

ORIGINAL PAPER

Pylorus Preserving Supracolic Dissected Pancreaticoduodenectomy with Binding Pancreaticojejunostomy

Ganguly N. Narendra¹, Bhattacharjee Nilotpal²

Received on December 14, 2016; editorial approval on March 05, 2017

ABSTRACT

Patients suffering from periampullary cancers undergo pancreaticoduodenectomy. A standard R0 resection is advisable for a fair survival. Complications after this procedure hover between 2% to 7% in different institutes and high output centers. The Achilles' heel of this procedure is the pancreaticoenteric anastomosis. From simple pancreaticojejunal anastomosis to duct to mucosa, dunking, pancreaticogastrostomy with or without antral opening to binding pancreaticojejunostomy are followed in different institutes. The supracolic dissection makes the approach to the pancreatic mesentery easy. However pylorus preserving procedure makes gastrostomy difficult. In such a situation we present our small experience on the subject and the results herewith. From 2003 to 2011 we have taken up patients for Whipple's surgery in our unit. We could operate on the six patients who were a part of almost 50 patients who were ultimately found to be operable. Few patients underwent Triple bypass and at least one patient we closed without any procedures because of the advanced nature of the disease. There was no operative mortality. One death on the 12th post op day due to ARDS(?) in the ICU. One died after 30 days. But all the patients were well after surgery. At least one patient survived over 24 months. The procedure mentioned here is worth a try.

Keywords: Periampullary cancers, Whipple's, Pancreaticoenterostomy, pancreaticoduodenectomy, R0 resection, pylorus preservation, supracolic dissection

INTRODUCTION

Pancreaticoduodenectomy (PD) is a complex surgical procedure. The procedure, which is also known as Whipple's procedure, is performed for periampullary cancers primarily. It can be safely said that this is one procedure which has a number of variants. The reasons for this procedure getting special attention are many. The prominent amongst them are difficult anatomy of the area,

the leakage rate, high mortality and morbidity rate after the surgery and differences of survival between the patients suffering from cancer of the lower bile duct and the pancreas head. Involvement of the Portal vein makes the area more complex for an RO clearance too. Certain deviations are followed in different institutes as per the institutional philosophy. Certain variants like binding pancreaticojejunostomy, supracolic dissection of the duodenum and pylorus preservation are some of the additional features suggested for a safer Whipple's procedure.

Here we present our experience gained on 6 such patients.

MATERIAL AND METHODS

6 patients, 5 male and one female patient underwent the procedure. All patients were detected with Cancers around the head of pancreas. The male patients were from 46 - 62 Years, the female was 66 years old. All had varying level of raised Bilirubin (From 11 to 19mg/dl.). These patients were serially selected for the procedure mentioned and the Patients were prepared for Whipple's procedure and preceded with pylorus preserving supracolic dissected pancreaticoduodenectomy with binding pancreaticojejunostomies.

PROCEDURE

Abdomen was opened with a Chevron incision in all cases. Exploration was done to see any metastasis before proceeding with the dissection. The right hemi colon as well as the Transverse colon was widely mobilized first and Kocherization was done to Aorta. We perform an extended Kocherization so that the Pancreas body rests well over the operating hand. In addition this helps in identifying the retro pancreatic spread of the disease

Address for correspondence:

¹Associate Professor of Surgery (**Corresponding Author**)

Email: drganguly@yahoo.com

Mobile: +919435043449

²Assistant Professor of Surgery, Jorhat Medical College, Jorhat

to Superior mesenteric artery. This is a crucial step as Involvement of the superior mesenteric artery as well as the root of the transverse mesocolon is considered to be of poor post operative survival. The Gastro duodenal artery is suture ligated once the lesser omentum is dissected. At this stage we make a tunnel to encircle the neck of the pancreas, thereby avoiding the point of no return. The gall bladder is dissected and common duct is transected at the end of the CHD. The neck is transected with Diathermy. The Duct is usually transected with sharp instruments. At this stage the wide and extensive Kocherization helps in separation of the Mesentery from the Portal vein and superior Mesenteric artery. This step is meticulous and takes up most of the operative time. As the neck is transected, attention is diverted to the Pylorus and the ligament of Treitz. Pylorus is transected at the prepyloric vein. Jejunum is delivered to the supracolic compartment and transected at the level of the second Jejunal artery. The whole block is removed en block with the dissected fibro fatty tissues , which include the nodes and the lymphatics. All bleeding points are managed at this stage before any anastomosis is undertaken. The pancreas is freed from all attachment for a distance of 3-4 centimeters. The end of the jejunum is inverted over itself. 3 centimeters of the Jejunal mucosa is destroyed and slid over the pancreas body. We always did a duct to mucosa anastomosis before sliding over the end of the jejunum in all cases. The binding ligature is applied over a Lahey forceps. A few retaining sutures are also placed to secure the pancreas to remain inside the sleeve, which of course is not necessary as per the original authors. A hepaticojejunostomy and a jejunojejunostomy complete the procedure. We routinely create a feeding jejunostomy and drain the area and closed in a standard manner.

Operating time varied from 4hours 30 (Female) minutes to 9 hours (male). Total Blood loss was minimal (<300ml.) in all patients. All patients recovered well and smoothly from anaesthesia. All patients were ICU observed for 24 hours and shifted to the wards on the third post operative day. Oral liquids started the next day as per our early feeding principle and solid allowed on day 4 in all patients.

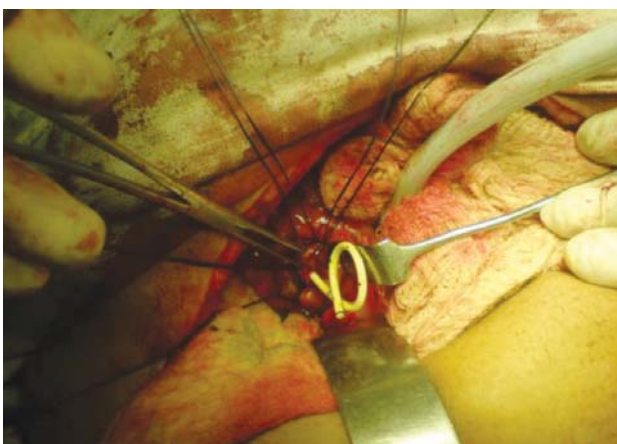


Figure 1 One of the cases who had a stent placed

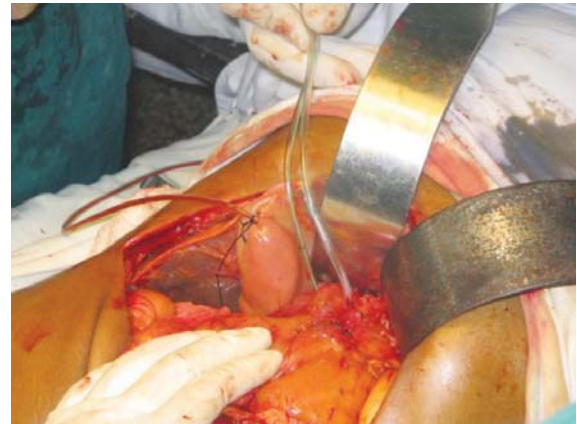


Figure 2 Supracolic dissection

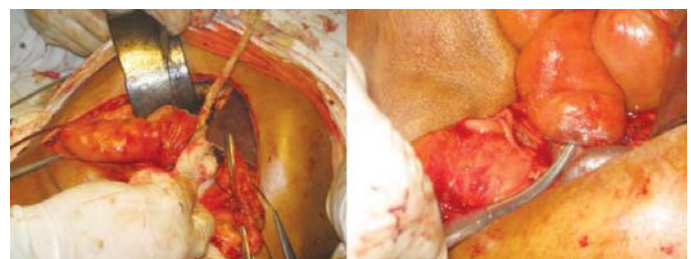

Figure 3 (a) Jejunum everted for Peng's procedure, (b) Binding PJA

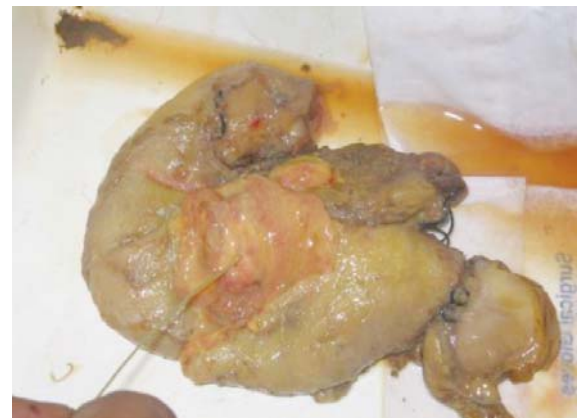

Figure 4 Total Specimen

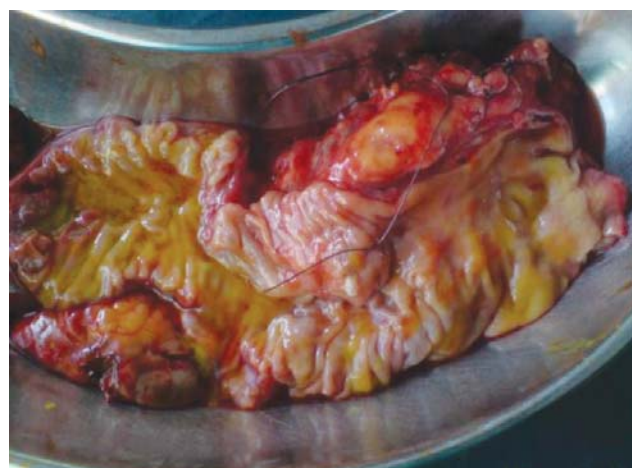

Figure 5 Whipple's specimen Split

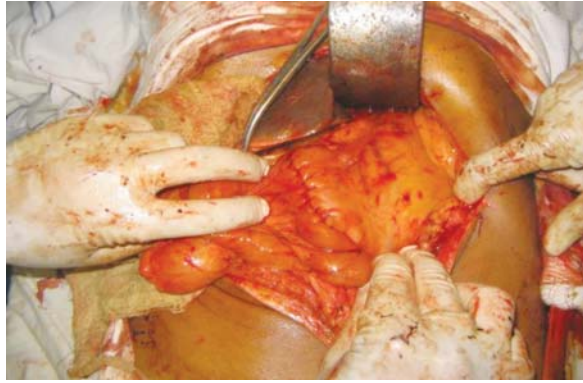


Figure 6 GJA, Completion of Procedures

RESULTS AND OBSERVATION

One male patient (62 Years old) Developed sepsis and developed wound abscess. The wound collection was drained and

Antibiotics started with the support of the Culture and sensitivity report. Discharge from the wound was tested for pancreatic enzymes and the enzyme levels found to be normal. This particular patient was on normal diet and was passing stool and flatus normally. Fistula was ruled out and repeat culture and sensitivity was periodically undertaken. This Patient died 32 days post operative. The female patient was normal till the 8th evening. She developed respiratory distress on the night of 9th post op day. The patient was shifted to the ICU. Expired on day 12 due to severe chest problem. Both the cases were on normal diet, passing stool and urine and had near normal liver function on the day of death. Rest of the patients behaved normally. They were discharged from hospital from 9th to 11th post operative day. Two came for regular checkups for over 12 months. One male patient 46 years old, developed secondaries in liver 18 months post surgery and the second was well upto 24 months after surgery and then lost to follow up.

Table 1 Briefly summarizing the patients particular

Pt.	Age/Sex	Disease	Procedure	Outcome	Remarks
A	46/M	Periampullary ca	Pylorus Preserving supracolic Dissected PD with Binding PJA	Survived	Followed up over 14 months
B	55/M	Periampullary ca	Do	Survived	Followed up over 9 months
C	66/F	Periampullary ca	Do	Died 10th Post op. day	ARDS, No leakage
D	60/M	Periampullary ca	Do	Survived	Followed up over 9 months
E	62/M	Periampullary ca	Do	Died after 30 days	Sepsis, No leakage
F	58/M	Periampullary ca	Do	Survived	Lost after one month check up

DISCUSSION

Whipple's procedure is almost a routine procedure in any well equipped centre and wherever there are surgeons to take up the surgical exercise. The extent of the procedure varies from surgeon to surgeon as well as institutional philosophy. The range of resection extends from mere Pancreaticoduodenectomy to pylorus preserving and radical/ extended lymph gland dissection (R0) to portal vein excision. Whatever is the correctness of the procedure the main components of the procedure are resection of the pancreas, duodenum, lower end of the CBD along with hepaticojejunostomy, pancreaticojejunostomy/ pancreaticogastrostomy and jejunojunctionostomy. Out of these three anastomoses, leakage of pancreas is the most dreaded and important reason of mortality as well as morbidity of the procedure. Much has been discussed about how to reduce the risk of this leak and many methods tried. The routine use of sandostatin to reduce the leak rate has also fallen into disfavor. At this juncture the binding pancreaticojejunostomy is worth consideration. Similarly the concept of duodenal mesentery and total supracolic dissection leaves the infra colic compartment free from handling thereby reducing the chance of prolonged paralytic ileus.

Pancreaticoduodenectomy is a difficult procedure. Although the procedure goes by the name of Whipple's procedure, its progress was started by Codivilla in 1898.¹ He of course did not do the pancreaticoenteric anastomosis and merely ligated the stump of the pancreas end. It was Kausch in 1921, who in a two stage procedure performed Pancreaticoduodenectomy and later did a pancreaticojejunostomy.² Whipple did the first procedure in 1946³ and it was Cattel who finally understood the death of the post surgery patients due to pancreatic juice leakage and suggested pancreaticoenterostomy in all patients undergoing Pancreaticoduodenectomy.⁴

Although the present rate of pancreatic fistula is stated to be around 2%^{5,6} in exceptionally good and skilled hands, the rate varies from 10% to 20% in various specialized centers.⁷⁻¹¹ To avoid this dreaded condition many hypothesis are suggested for the causes. Soft Pancreas, small duct size (<2mm) and high juice output¹⁶ are considered to be the triad of danger. Similarly performing a parachuting technique of implantation of the stump to the jejunum to simply connecting the stump to the posterior wall of the stomach^{13,14,15,16} could not achieve safety from the leakage of the anastomosis.^{13,14,15} A new method of binding pancreaticojejunostomy was suggested from China with 100% leak proof results.^{12,18}

Meanwhile a new concept of the mesentery of duodenum has taken ground and its practicality was shown by some of the surgeons. Even variations in this technique are followed these days like SMA hanging technique.¹⁹ They performed the whole dissection of the Whipple's procedure from the supracolic compartment only. This simple technical modification led to simplifying of such a big procedure and is presently being evaluated worldwide

Presently the pylorus preserving Pancreaticoduodenectomy is also favored by many.¹⁶ Simultaneously the overzealous Japanese radical associated gland dissection was gaining disfavor amongst the Japanese surgeons themselves and presently the opinion is in favor of routine gland clearance only (Prof. Nimura, unpublished data).

Considering all the aspects it can be said to be a procedure needing attention. The result obtained and experience gained by undertaking the procedure was worthwhile since the patients survived the difficult, new and intricate procedure better than recognized international average (Metanalysis of survival after PD, 2010).

CONCLUSION

In the conclusion it can be said that surgery of cancer pancreas has changed in the last two hundred years. The international experience, especially the Japanese workers', has settled the question of the extent of dissection required for the procedure. Doing anything less than that of the regular node dissection along with Pancreaticoduodenectomy for cancer head of pancreas and periampullary cancers is probably not advisable in today's scenario. R0 resection is preferable these days. The procedure mentioned here matches the otherwise a standard Whipple's procedures in different institutes and should be given attention.

Conflicts of interest: No conflict of interest is associated with this work.

Contribution of Authors: We declare that this work was done by the authors named in this article and all liabilities pertaining to claims relating to the content of this article will be borne by the authors.

Ethical clearance: Taken from Institutional Ethical Committee.

REFERENCES

- Whipple AO, Howard JM, Jordan GL, Jr JB. A historical sketch of the pancreas, *Surgical Disease of the Pancreas*. Lippincott: Philadelphia; 1960. p. 1–8.
- Kausch W. Das carcinoma der papillaa duodenei un seine radikale entfernung. *Beitr Klim Chir* 1912;78:439-86.
- Whipple AO. Observations on radical surgery for lesions of the pancreas. *Surgery Gynecology and Obstetrics* 1946;82:623-31.
- Cattell BB. Resection of the pancreas, Discussion of special problem. *Surgclin North Am* 1943;23:753-66.
- Poon RTP, Lo SH, Fong D. Prevention of pancreatic anastomotic leakage after Pancreaticoduodenectomy. *Am J Surg* 2002;183:42-5.
- Buchler MW, Freiss H, Wagner M. Pancreatic fistula after pancreatic head resection. *Br J Surg* 2000;87:833-99.
- Strasberg SM, Drebin JA . Prospective trial of a blood supply based technique of pancreaticojejunostomy: effect on anastomotic failure in the Whipple procedure. *J Am Coll Surg* 2002;194:746-58.
- Yeo CJ, Cameron JL Lillemore KD. Does prophylactic octreotide reduce the rate of pancreatic fistula and other complications after Pancreaticoduodenectomy? Results of a prospective randomized controlled trial. *AnnSurg* 2000;232:419-29.
- Grobmeyer SR, Rivedenera DE, Goodman CA. Pancreatic anastomotic failure after Pancreaticoduodenectomy. *Am J Surg* 2000;180:117-20.
- Ohwada S, Ogawa T, Kawate S. Results of duct to mucosa pancreaticojejunostomy for Pancreaticoduodenectomy Billroth I type reconstruction in 100 consecutive cases. *J Am CollSurg* 2001;193:29-35.
- Kakita A, Yoshida M, Takahasi T. History of pancreaticojejunostomy in Pancreaticoduodenectomy: Development of a more reliable anastomotic technique. *J hepatobiliary Pancreat Surg* 2001;8:230-7.
- SY Peng, JW Wang, JT Li, YP mou. Binding pancreaticojejunostomy- a safe and reliable anastomosis procedure. *HPB* 2004;3:154-60.
- Kannan N, Gupta S. Technique of pancreaticogastric anastomosis without anterior gastrotomy: a point of view. *Ind J Surg* 2006;68:233.
- Jewery M, Shukla HS. Anterior gastrotomy technique of fashioning pancreaticogastrostomy following Pancreaticoduodenectomy for cancer of head of pancreas and periampullarycancers. *Ind J Surg* 2005;67:276-82.
- B M Kapur, M C Misra, V Seenu, A K Goel. Pancreaticogastrostomy for reconstruction of pancreatic stump after pancreaticoduodenectomy for ampullary carcinoma. *Am J Surg* 1998 Sep;176(3):274-8.
- Takada T, Yasuda H. Pancreatic enzyme activity after a pylorus preserving Pancreaticoduodenectomy reconstructed with pancreaticogastrostomy. *Pancreas* 1995;11:276-82.
- Aranha GV, Hodul P, Golts. A comparison of pancreaticogastrostomy and pancreatico jejunostomy following Pancreaticoduodenectomy. *J Gastrointest Surg* 2003;7:672-82.
- SY Peng, JW Wang, JT Li, YP mow. Bindingpancreaticojejunostomy: 150 consecutive cases without leakage. *J Gastrointest Surg* 2003;7:898-901.
- YosukeInoue, AkioSaiura, Masayuki Tnaka . Technical details of an anterior approach to the superior Mesenteric Artery during Pancreaticoduodenectomy. *J Gastrointest Surg* 2016;20:1769-1777.