

**Table 5** Level of significance of differences of number and diameter of lymphoid follicle

Serial number	Comparison of mean between	“t”	P
1	Number of lymphoid follicle of children (0 to 14 years) & adult (20 to 50 years)	2.402	<0.05
2	Diameter of lymphoid follicle of children (0 to 14 years) & adult (20 to 50 years)	1.775	<0.05

## DISCUSSION

The appendix is an evagination of the caecum characterized by a relatively small, narrow, and irregular lumen due to presence of abundant lymphoid follicles. It contains fewer and shorter intestinal glands and has no teniae coli.<sup>14</sup>

A lot of research has been conducted till date on the microanatomy of appendix. Appendix is characterized by a great increase in the lymphoid tissue, the nodules occupying a large part of both mucous and sub mucous coat, the muscularis mucosa is rather deficient. The glands are much less closely packed than in large intestine. They are most numerous in early life and tend to disappear in old age. The lumen of appendix itself is often obliterated in later life. Researchers like Foster,<sup>15</sup> Bloom & Fawcett,<sup>16</sup> Copenhaver *et al*,<sup>17</sup> Plessis,<sup>18</sup> Borysenko and Beringer,<sup>19</sup> Cormack,<sup>20</sup> Telford and Bridgman,<sup>21</sup> have described the microanatomy of the appendix elaborately. In most of the studies the number and diameter of the lymphoid follicles of appendix are more in children than the adult.

Our study is consistent with this universal observation. Number and diameter of lymphoid follicle of appendix have been measured in matched sets of observation using the null hypothesis: Reject  $H_0$  if  $P < t_a$  when  $t_a = t_{0.05}$  setting the level of confidence at 95% probability signifying that if the differences in observation between the matched groups is significant at the level of  $P < 0.05$ , the hypothesis will be rejected establishing differences in length between the tested groups.

## CONCLUSION

The average number of the lymphoid follicle of appendix in the age group of ‘0 to 14’ years is  $11.900 \pm 1.649$ . The average number of the lymphoid follicle appendix in the age group of ‘20 to 50’ years is  $7.636 \pm 0.855$ . The average diameter of the lymphoid follicle of appendix in the age group of ‘0 to 14’ years is  $120.780 \pm 14.890 \mu\text{m}$ . The average diameter of the lymphoid follicle of appendix in the age group of ‘20 to 50’ years is  $91.500 \pm 7.092 \mu\text{m}$ .

We can have an inference that the number of the lymphoid follicle of appendix in the age group of ‘0 to 14’ years is more than the age group of ‘20 to 50’ years, which is significant ( $P < 0.05$ ) as evident in **table 5**. On the other hand the diameter of the lymphoid follicle of appendix in the age group of ‘0 to 14’ years is more than the age group of ‘20 to 50’ years, which is significant ( $P < 0.05$ ), as evident in **table 5**.

Finally, under limitations of the present study it may be concluded that the number and diameter of lymphoid follicles of human

appendix both increases upto adolescent period only. Afterwards, it decreases with advancement of age.

**Acknowledgements:** We sincerely acknowledge the support of Dr. KL Talukdar, Professor, Department of Anatomy, Gauhati Medical College in carrying out the present study.

**Conflicts of interest:** No conflict of interest is associated with this work.

**Contribution of authors:** We declare that this work was done by the authors named in this article and all liabilities pertaining to claims relating to the content of this article will be borne by the authors.

**Ethical clearance:** Taken from institutional ethical committee.

## REFERENCES

- Junqueira LC, Carneiro J, Contopoulos AN. Digestive tract. Basic Histology. 2<sup>nd</sup> ed. Brazil: Springer; 1971. p. 308.
- Golalipour MJ, Arya B, Azarhoosh R, Jahanshahi M. Anatomical variations of vermiform appendix in south-east Caspian sea (Gorgan-IRAN). J of Anat Soc of India 2003;52(2):141-3.
- Schwartz SJ, Shires GT, Spencer FC, Dally JM, Fischer JE, Galloway AC. The appendix. Principles of surgery 1999;7(3):1383-5.
- Liu CD, McFadden DW. Acute abdomen and appendix. Scientific Principles and Practice in Surgery. 2<sup>nd</sup> ed. Germany: Medscape; 1997. p. 1246-61.
- Fawcett DW, Raviola E. Bloom and Fawcett. A textbook of histology. 6<sup>th</sup> ed. USA: Chapman and Hall; 1994. p. 292.
- Wakely CP. The position of the vermiform appendix as ascertained by analysis of 10,000 cases. J Anat 1993;67:277.
- Young B, Lowe JS, Stevens A, Heath JW. Gastrointestinal tract. Wheater’s Functional Histology. 5<sup>th</sup> ed. France: Elsevier; 2007. p. 285.
- Borley NR, Healy JC. Large intestine. Abdomen and pelvis. Gray’s Anatomy. 40<sup>th</sup> ed. London Churchill Livingstone: Elsevier; 2008. p. 1143.
- Hollinshead WH. The Jejunum, Ileum & Colon. Anatomy for Surgeons. 2<sup>nd</sup> ed. Philadelphia: Joanna Cotler Books; 1972. p. 484.
- Plessis DDJ. The gut. Chapter IX. A synopsis of surgical Anatomy. 11<sup>th</sup> ed. Baltimore: Williams & Wilkins; 1984. p. 59.
- Townsend CM, Beauchamp RD, Evers BM, Mattox KL. The appendix. Chapter 49. Sabiston Textbook of Surgery. 18<sup>th</sup> ed. Germany: Saunders; 2009. p. 1333.
- Dutta AK. The alimentary system. Essentials of Human Anatomy. Thorax and Abdomen. 8<sup>th</sup> ed. Kolkata: Current Books International; 2008. p. 221.
- Stranding S. Large intestine. Abdomen and Pelvis. Section 8. Gray’s Anatomy. 40<sup>th</sup> ed. London Churchill Livingstone: Elsevier; 2008. p. 1143.
- Junqueira LC, Carneiro J, Contopoulos AN. Digestive tract. Chapter16. Basic Histology. 2<sup>nd</sup> ed. Brazil: Springer; 1971. p. 308.
- Foster CL. Vermiform Appendix. The digestive system. Large intestine. Chapter XXV. Hewer’s Textbook of Histology for Medical Students. 8<sup>th</sup> ed. London: Elsevier; 1964. p. 303.
- Bloom W, Fawcett D. Intestine. Chapter27. A textbook of histology. 10<sup>th</sup>ed. Philadelphia: Saunders; 1975. p. 674.
- Copenhaver MW, Kelly DE, Wood LR. The Digestive System. Chapter16. Baileys Textbook of Histology. 7<sup>th</sup> ed. Philadelphia: Williams & Wilkins; 1978. p. 509-10.
- Plessis DuDJ. The gut. Chapter IX. A synopsis of surgical Anatomy, 11<sup>th</sup> ed. Johannesburg: Bristol; 1984. p. 59.
- Borysenko M, Beringer T. Oral cavity & Alimentary tract. Chapter14. Functional Histology. 3<sup>rd</sup> ed. New York: Little Brown and Company; 1989. p. 328.
- Cormack DH. The digestive system. Chapter13. Essential Histology. 1<sup>st</sup>ed. Philadelphia: J.B. Lipincott Company; 1993. p. 291.
- Telford IR, Bridgman CF. Digestive system II. Chapter18. Introduction to Functional Histology. 2<sup>nd</sup> ed. New York: Harpercollins College Div; 1994. p. 326.

## ORIGINAL PAPER

# Dental morphological anomalies in the adi Tribe of pasighat in Arunachal Pradesh

Das Lima<sup>1</sup>, Bhuyan AC<sup>2</sup>, Kataki Rubi<sup>3</sup>, Kalita Chandana<sup>4</sup>

Received on October 26, 2017; editorial approval on November 23, 2017

### ABSTRACT

**Objective:** To identify three dental morphological anomalies of permanent teeth namely Peg Laterals, Dens Evaginatus and Rudimentary third molars in the Adi tribe of Pasighat area of Arunachal Pradesh. **Methods:** Oral examination for morphological anomalies was done in 156 individuals using a dental mirror and probe for the said anomalies and a questionnaire with details relevant to the study was used during examination. **Results:** A total of 156 samples were screened and 35% presented with at least one anomaly out of which 31% had one anomaly, 4% had two anomalies and 0% had more than two anomalies. Total number of positive cases (both single and dual) for each of the anomalies was- Peg Laterals 25%, Dens Evaginatus 20% and Rudimentary third molar 4%. One other anomaly, i.e. Cusp of Carabelli not previously considered in this study was found in 22% of the cases. **Conclusion:** The data obtained from the present study confirms the prevalence of dental anomalies namely, Peg Laterals, Dens Evaginatus, Rudimentary third molars and Cusp of Carabelli in the tribal population of Pasighat similar to other Mongoloid populations of the world.

**Keywords:** Cusp, Peg Laterals, Dens Evaginatus, Rudimentary third molars, Cusp of Carabelli

### INTRODUCTION

Dental morphological anomalies in permanent teeth are an important area of study within the subject of Dental Anatomy and Physiology. There are several reasons for studying dental anatomical variants in any population, the most significant being **enhanced diagnosis and treatment planning**. Early diagnosis of dental anomalies allow for more comprehensive treatment planning, better prognosis and in certain instances, less extensive interception.<sup>1</sup> Another important reason for studying anatomical variation is for **forensic value**. Anatomical variation related to tooth morphology may show

certain traits specific to different racial groups which may be of immense forensic value. Ancestry can be accessed by studying the facial skeleton and comparing the features with the main characteristics of three racial groups: Mongoloid, Negroid, and Caucasoid.<sup>2</sup> Also, the large variation in morphological features and their form may not be easily altered; thus a trait of the human dentition can be a valuable diagnostic tool for **anthropological studies** in classifying and characterizing different ethnic groups.<sup>3</sup> Accumulation of data on the morphological traits of teeth in different populations has let anthropologists to research further on the evolutionary significance of this data and consider its mode of inheritance. Again the incidence and degree of expression of anomalies in different population groups can provide important information for phylogenetic and genetic studies and help the understanding of variations within and between the different world populations.<sup>4</sup>

However, the occurrence of dental morphologic anomalies has not been adequately researched in the remote tribes and sub-tribes of north-east India. The present study will not only contribute towards a better understanding of the said topic but will also provide a base line data for allied branches to review.

An initial hypothesis related to the present research is as follows-Three dental anomalies of permanent teeth namely Peg Lateral, DensEvaginatus and Microdontia of third molars

---

#### Address for correspondence:

<sup>1</sup>Reader (Corresponding Author)

Email: limakaling@gmail.com

Mobile: +919954714031

<sup>2</sup>Professor and Head, <sup>3</sup>Professor, <sup>4</sup>Reader

Dept. of Conservative Dentistry & Endodontics  
Regional Dental College, Guwahati, Assam

are endemic in the Adi population of Pasighat, in Arunachal Pradesh.

**Objectives:** The aim of the study is to identify three dental morphological anomalies namely Peg laterals, Dens Evaginatus and Microdontia of maxillary third molars/Rudimentary third molars (erupted) in the tribal population in Pasighat area of Arunachal Pradesh, India.

The overall objective of the proposed study was to establish through data the occurrence of dental morphological anomalies in permanent teeth in the said population.

#### METHODS

Oral examination was done using dental mirror and probe for the said anomalies and a questionnaire with details relevant to the study was used during examination. The age group selected was above 21 years. A stratified cluster sampling method for data collection was used after dividing the said Pasighat area into three main geographical groups and further stratifying them into sub groups. The three main groups are: Pasighat urban subdivision (gr 1), Balek group of villages (gr 2) and Mirmir group of villages.

A total number of 156 samples were screened in this present study distributed in the three main groups in the ratio 12:2:5 according to population ratio. Geographical area concerned with the study includes the entire Pasighat township within 10 km radius.

**Inclusion & exclusion criteria were considered as follows:**

**Inclusion criteria:** Persons belonging to the Adi tribe and age should be above 21 years.

**Exclusion criteria:** If one or both parents are not from the Adi tribe, restored teeth and unerupted third molars.

Study variables such as sub tribes of the Adi tribe (e.g: pasi, padam, panggi, minyong, milang), gender, type of anomaly and geographical distribution were considered.

#### Definitions:

Peg Laterals are maxillary lateral incisors in which the mesial and distal sides converge or taper together incisally forming a peg shaped or cone shaped crown instead of exhibiting parallel or diverging proximal surfaces. Dens Evaginatus is a developmental condition that appears clinically as an accessory cusp or a globule of enamel usually on the occlusal surface between the buccal and lingual cusps of premolars unilaterally or bilaterally. Again, microdontia of third maxillary molars/rudimentary third molar are third molar teeth that are smaller in size than normal, i.e., outside the usual limits of variations.<sup>5</sup>

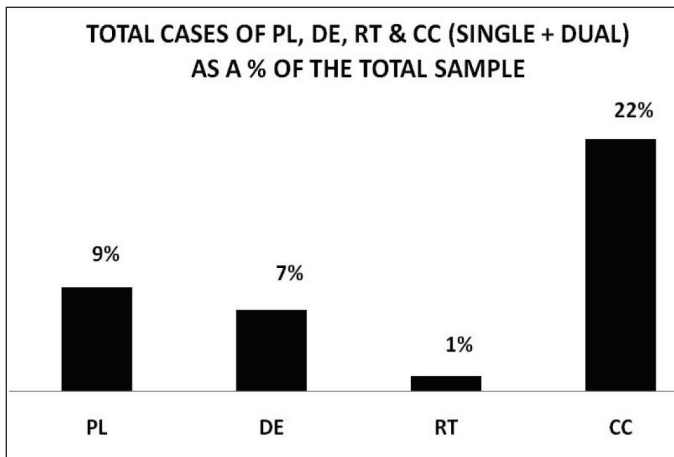
Ethical clearance was taken from the institutional ethics committee. Data analysis was done using IBM SPSS version 20 and Microsoft Excel Spreadsheet software.

#### RESULTS

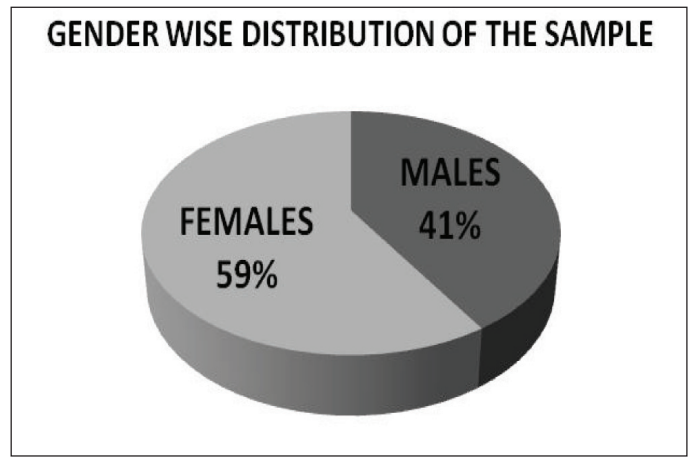
Oral examination showed the presence of three previously mentioned anomalies Peg laterals, Dens Evaginatus and Microdontia of third molars and also included positives of one other anomaly, i.e. Cusp of Carabelli in a number of the cases. Of the total sample of 156 the number of cases with anomalies was 55, i.e. 35% of the total cases screened. Of the total 156 samples number of Cusp of Carabelli found were 34, i.e., 22%, Peg laterals (PL) 14, i.e. 9%, Dens Evaginatus (DE) 11 i.e., 7%, Microdontia of third molars (RT) were 2 i.e., 1%. Of the positive 55 cases the number and percentage of individual anomalies (both single and dual) are Cusp of Carabelli 34, i.e., 62%, Peg laterals (PL)14, i.e., 25%, Dens Evaginatus (DE) 11, i.e., 20%, Microdontia of third molars (RT) 2, i.e., 4% Again, the prevalence of anomalies was 59% in the females and 41% in the males (**Figure 2**). The distributions of anomalies in the various sub-tribes were Pasi-18%, Padam - 16%, Milang - 2%, Panggi - 4% and Minyong - 60% (**Figure 3**). Geographically, 45% of the anomalies were found in the urban area, 24% in the Balek area and 31% in the Mirmir area (**Figure 4**).

**Table 1** Number and percentage of occurrence of anomalies out of the total samples and among the positives

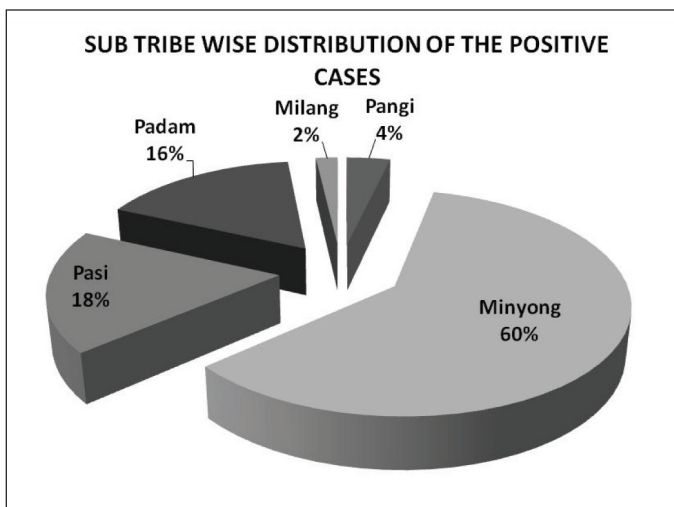
Descriptive Statistics	Observed values	% of total sample (156)	% of positive cases (55)
	Total no. Of screenings (sample size)	156	
No. Of positive cases	55	35%	
No. Of cases with one anomaly	49	31%	89%
No. Of cases with two anomalies	6	4%	11%
No. Of cases with more than two anomalies	0	0%	0%
No. Of pl positive cases	14	9%	25%
No. Of de positive cases	11	7%	20%
No. Of rt positive cases	2	1%	4%
No. Of cc positive cases	34	22%	62%



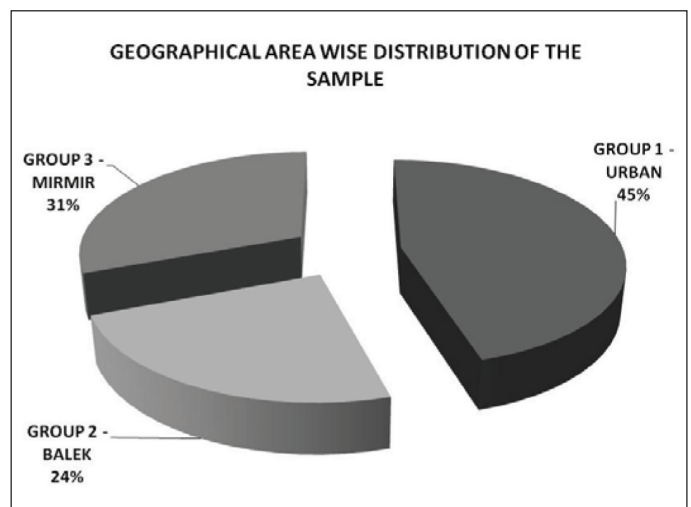
**Figure 1** Distribution of anomalies as a percentage of the total sample



**Figure 2** Gender-wise distribution of anomalies



**Figure 3** Distribution of anomalies according to the sub-tribes



**Figure 4** Geographical distributions of anomalies

**DISCUSSION**

The occurrence of dental morphological anomalies has been studied by various authors in different world populations at various times. However such studies identifying dental morphological traits in the various tribes and sub-tribes of the north-eastern states of India have not received its due importance.<sup>3, 6, 7</sup>

In the present study, of the total number of 156 cases, 35% presented with at least one anomaly. 31% of the total cases had one anomaly, 4% had two anomalies and none had more than two anomalies. It was observed that 9% of the total cases were positive for Peg Lateral, 7% for Dens Evaginatus, 1% for rudimentary third molar and 22% for Cusp of Carabelli. Again to statistically analyze the results A ‘Z’ test of proportion was done to test the difference between the hypothesized proportion of anomalies (P=50%) and the observed proportion (p=35%) at 5% significance level. The Z test indicated that the p value < 0.05.

Chi square tests were conducted at 5 % significance level to test the difference in the distribution of anomalies according to gender, area and the various sub tribes. The tests indicated that there is

no significant difference in the distribution of anomalies with respect to gender (p value = 0.85). However, highly significant differences were indicated in the distribution of the anomalies with respect to area (p value <0.001) and to sub tribe (p value< 0.001).

A study similar to our present study was done by Nayak P in Rajasthan and he found that prevalence of peg lateral was 0.4% which is very less compared to the 9% prevalence in our study.<sup>8</sup> Hua F also did a meta analysis on the prevalence of peg-shaped maxillary permanent lateral incisors and their associations with race, population type, sex, and sidedness.<sup>9</sup> The overall prevalence of peg-shaped maxillary permanent lateral incisors was 1.8%, the occurrence rates being higher in Mongoloid (3.1%) than in black (1.5%) and white (1.3%) patients. Comparatively the findings in our study showed a higher percentage of prevalence of Peg laterals. In his study women were more likely than men to have peg shaped maxillary permanent lateral incisors. The prevalence rates of unilateral and bilateral peg-shaped maxillary permanent lateral incisors were approximately the same. However, among the unilateral lateral incisors, the left side (0.4%) was twice as



common as the rightside (0.2%). Another similar study on the dental features such as size, shape, cusp number and groove pattern, etc. was done on the Tibetan immigrants of India by Sharma J.<sup>10</sup> He concluded that overall reduction in size, hypodontia of the third molar and absence of Carabelli's Cusp were a distinct evolutionary trend in Tibetan dentition. In our study however the prevalence of the Cusp of Carabelli was much higher, i.e. 22%. In another study by Stecker SS the prevalence of dental anomalies in a Southeast Asian Population in the Minneapolis area reported a higher 7.5% prevalence of peg laterals and 1.1% of Dens Evaginatus in Asians.<sup>11</sup>

In our study since no previous data relating to the prevalence of dental morphological anomalies in the Adi tribe was found, population proportion (P) with anomalies was hypothetically taken as 50%. The observed proportion following data collection and analysis was 35%. The Z test used to compare the two proportions rejected the null hypothesis. However the higher prevalence rate confirmed the presence of specific types of dental anomalies and has given us their prevalence rates for future studies.

#### CONCLUSION

The data obtained from the present study confirms the prevalence of dental anomalies, namely Peg Lateral, Dens Evaginatus, Microdontia of third molars and Cusp of Carabelli in the Pasighat area of Arunachal Pradesh

**Conflict of interest:** No conflict of interest associated with this work.

**Ethical clearance:** Taken.

**Source of funding:** None declared.

**Author declaration:** We declare that this work was done by the authors named in this article and all liabilities pertaining to claims relating to the content of this article will be borne by the authors.

#### REFERENCES

1. Yonezu T, Hayashi Y, Sasaki J, Machida Y. Prevalence of congenital dental anomalies of the deciduous dentition in Japanese children. *Bull Tokyo Dent Coll* 1997;38:27-32.
2. Leung KK. Forensic odontology. *Dent Bull* 2008;13:11.
3. King N M, Tsai Jennie S J, Wong H M. Morphological and numerical characteristics of the southern chinese dentitions. Part II: Traits in the permanent dentition. *Open Anthropol J* 2010;3:71-84.
4. Patil S, Doni B, Kaswan S, Rahman F. Prevalence of dental anomalies in Indian population. 2013 Oct. [cited 2014 Jul];5(4): [e183–e186]. Available from: URL: <https://www.ncbi.nlm.nih.gov/pmc/articles/PMC3892239/>
5. Shafer WG, Hine MK, Levy BM. *Oral Pathology*. 5<sup>th</sup>ed. Singapore: Harcourt Brace Asia; 1993. p. 52-59.
6. Jerome CE, Hanlon RJ. Dental anatomical anomalies in asians and pacific islanders. *CDA J* 2007;35(9):631-6.
7. Lavelle CLB. A metrical comparison of maxillary first premolar form. *Am J Phys Anthropol* 1984;63:397-403.
8. Nayak P, Nayak S. Prevalence and distribution of dental anomalies in 500 Indian school children. *Bang J of med Sc* 2011;10(1).
9. Hua F, He H, Ngan P. Prevalence of peg-shaped maxillary permanent lateral incisors: a meta-analysis. *Am J of Orthod and Dentofacial Orthop* 2013;144(1):97-109.
10. Sharma J. Dental morphology and odontometry of the tibetan immigrants. *Am J Phys Anthropol* 1983;61(4):495-505.
11. Stecker SS, Beirahi S, Hodqes JS, Peterson VS. Prevalence of dental anomalies in a southeast asian population in the minneapolis/saint paul metropolitan area. *J of Minnesota dental assoc* 2013;92(4).