

CASE REPORT

A synonym to healing for perforation repair-MTA

Shekhawat Krutika¹, Bora Proxima², Katakhi Rubi³, Bhuyan AC⁴

Received on November 30, 2018; editorial approval on January 30, 2018

ABSTRACT

Root perforation is an iatrogenic communication between the root canal systems to the supporting tissues of teeth. Often, it is an accidental result of misaligned use of rotary burs during access preparation and location of root canal orifices. Other possible etiologic factors for perforation can be strip perforations during cleaning and shaping procedures, root resorption, defect created during post space preparation, perforation of floor of pulp chamber due to extension of carious lesion. The present case report throws light on the healing of rarefaction of the furcation area caused due to accidental perforation due to access cavity preparation. Endodontic treatment with placement of MTA as perforation repair material. Many materials have been reported as furcation repair materials but in the present case report MTA is used as a repair material which achieved excellent results. Mineral trioxide aggregate is a suitable material for the treatment of root perforations, with the goal of regenerating periodontal attachment.

Keywords: *Iatrogenic furcal perforation, Radiolucency, periodontal attachment*

INTRODUCTION

Mineral trioxide aggregate (MTA) has been regarded as an ideal material for perforation repair, retrograde filling, pulp capping, and apexification since its introduction in 1993.^{1,2} With longer duration, new cementum was found on the surface of the material.³ Regardless of the cause, a perforation allows bacterial invasion into the supporting structures that initially incites inflammation and loss of attachment, which eventually may compromise the prognosis of the tooth.^{4,5} Furcation perforation is followed by bacterial contamination, periradicular tissue injury, inflammation, bone resorption, periodontal fiber destruction, epithelium proliferation, and periodontal pocket development.⁶ A principle goal of endodontic therapy is to remove bacteria and seal the root canal to promote osseous regeneration.⁷ Several studies have demonstrated that perforation of the root surface complicates

our ability to achieve this goal.^{4,6} The aim of this long-term follow-up case report is to present a successful treatment of iatrogenic furcal perforation by MTA.

CASE REPORT ONE

A 22 year old male patient reported to the department of Conservative Dentistry and Endodontics, Regional dental college, Guwahati. Patient complained of pain and swelling in right lower region of jaw. On clinical examination: extraorally fluctuant swelling was present in mandibular region. Intraorally temporary dressing was seen with 46 and restoration with 45. On radiographic examination incomplete obturation was found with respect to 45 and radiolucency was seen in bifurcation area 46. Local anaesthesia was applied and rubber dam placed. Temporary dressing was removed with 46 and which was followed with profuse haemorrhage. After copious irrigation with 3% sodium hypochlorite haemorrhage was controlled and furcal perforation was detected. Canals were then located. The perforation was sealed with mineral trioxide aggregate, ProRoot MTA (Dental Tulsa; Dentsply) mixed in a 3:1 proportion. In this appointment, MTA was applied with MTA carrier, a moist cotton pellet was then placed in the pulp chamber to produce a humid ambient for MTA with the aim of achieving its solidification, and the tooth was temporarily filled with Cavit. In the next appointment the working lengths were determined both electronically and radiographically. The mesial and distal canals were cleaned and shaped using protaper (Dentsply Maillefer, Ballaigues, Switzerland) in a crown-down technique and copious irrigation with 5.25% sodium hypochlorite. Calcium hydroxide was placed as an intra canal medicament for 2

Address for correspondence:

¹Post Graduate Student (PGT) (Corresponding author)

Email: shekhawatkrutika@gmail.com

Mobile: +919954232356

²PGT, ³Professor, ⁴Professor and head cum Vice Principal
Department of Conservative Dentistry & Endodontics,
Regional Dental College, Guwahati

Cite this article as: Shekhawat Krutika, Bora Proxima, Katakhi Rubi, Bhuyan AC. A synonym to healing for perforation repair-MTA. *Int J Health Res Medico Leg Prae* 2018 July;4(2):99-101. DOI 10.31741/ijhrmlp.v4.i2.2018.24

weeks. After which the root canals were obturated with gutta-percha points and AH26 sealer. Simultaneously retreatment procedure was also performed with respect to 45. Patient was recalled after a week for regular check up. Patient was asymptomatic at 1 week recall. Then a follow up was done at 3, 6, 9 months which showed complete healing of the large bifurcation radiolucency.

CASE REPORT TWO

A 20 year old girl came to the Department Of Conservative Dentistry And Endodontics, Regional Dental College, Guwahati, Assam with the chief complaint of incomplete root canal treatment with anterior tooth. On examination temporary dressing was found with respect to 11. Local anaesthesia was administered followed by placement of rubber dam. On removal of dressing profuse bleeding was observed with 11. Bleeding was controlled with copious use of sodium hypochlorite and labial perforation was detected both clinically and radiographically. Working length was determined and biomechanical preparation was done and the tooth was obturated till the site of perforation with lateral condensation technique. MTA was placed over the perforation site and remaining pulp chamber was sealed with composite restorative material. During follow up after 1 week patient was found to be asymptomatic and no pathology was seen both radiographically and clinically at 3, 6, 9 months follow up.

DISCUSSION

Effective seal of root perforation is essential for prognosis of perforated teeth which would have been rather compromised. The first case report was that of accidental perforation during access cavity preparation where as second case presented with incomplete root canal treatment along with labial perforation defect. Two cases presented here were effectively sealed with MTA, which depicted favourable results as patients were asymptomatic after follow up visits. Radiographs revealed complete osseous healing.

In the past years, amalgam, composite resin and glass ionomer cements have been used for sealing furcal perforation. However, studies have shown that MTA is apparently superior to these materials with respect to marginal adaptation^{8,9,10-12}, bacterial leakage^{8,9,10-13} and cytotoxicity.^{8,14} MTA is a biocompatible material which when used in root-end cavities, stimulates reparation of periradicular tissues, showed no inflammation and deposition of cementum¹⁵ and the ability to induce hard tissue formation.¹⁶

Studies have shown that MTA actively promotes hard-tissue formation rather than being inert or an irritant like other materials^{17,18} The clinical applications also have proved that MTA is suitable for solving the problems derived from perforation. It does not interfere with the presence of moisture, and it inhibits the activity of bacteria.^{19,20,21,22}

CONCLUSION

Mineral trioxide aggregate is a suitable material for the treatment of root perforations, with the goal of regenerating periodontal attachment. In the above case reports, root

perforations were treated with MTA to seal the perforation site. The repaired teeth were clinically and radiographically healthy and continued to satisfy esthetic and functional demands. Based on the outcome of the cases presented, MTA is a good material for the repair of the perforation and has been proven effective for large perforations and those close to the coronal third of the root.

Though favourable results have been achieved in the above mentioned case reports but long term follow up studies need to be conducted.

Case 1

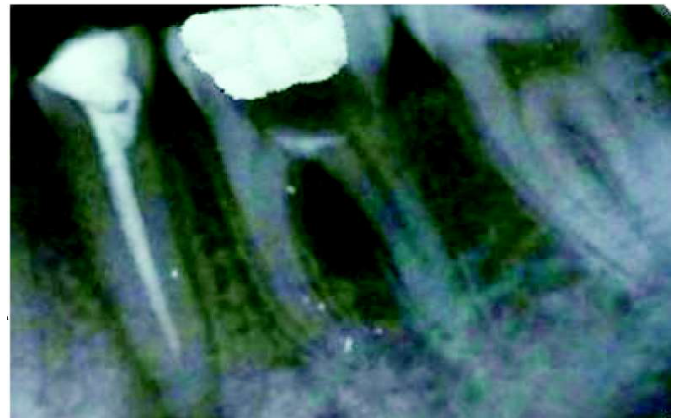

Figure 1 MTA placed in furcation area

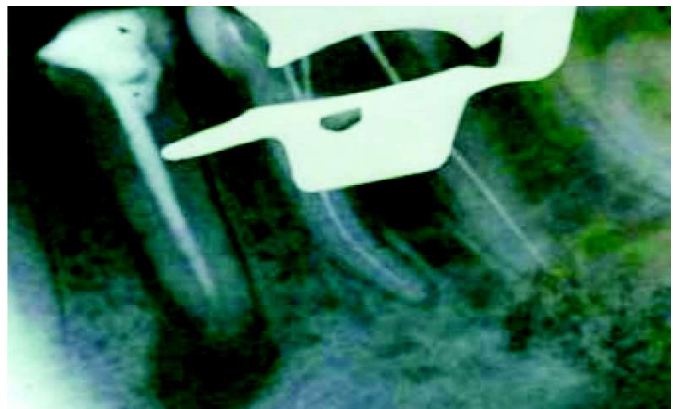

Figure 2 Working length determination

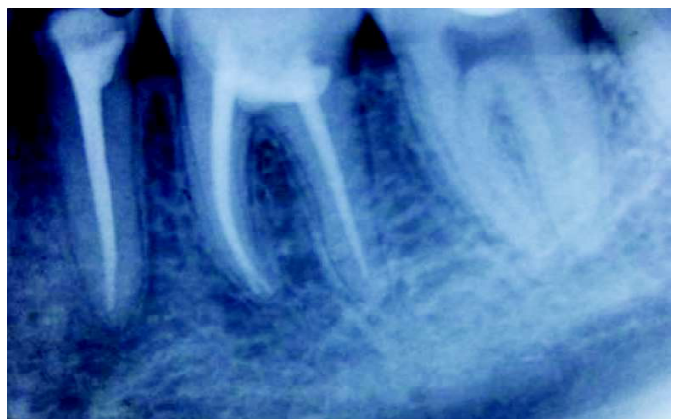


Figure 3 Post-operative follow up after 9 months

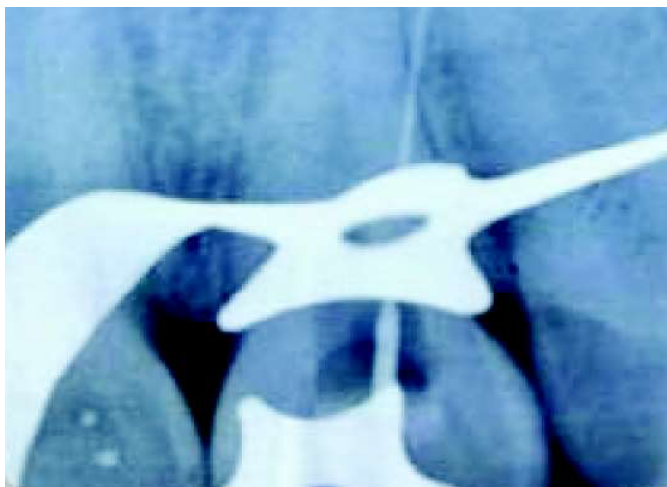Case 2

Figure 1 Perforation on labial surface of central incisor

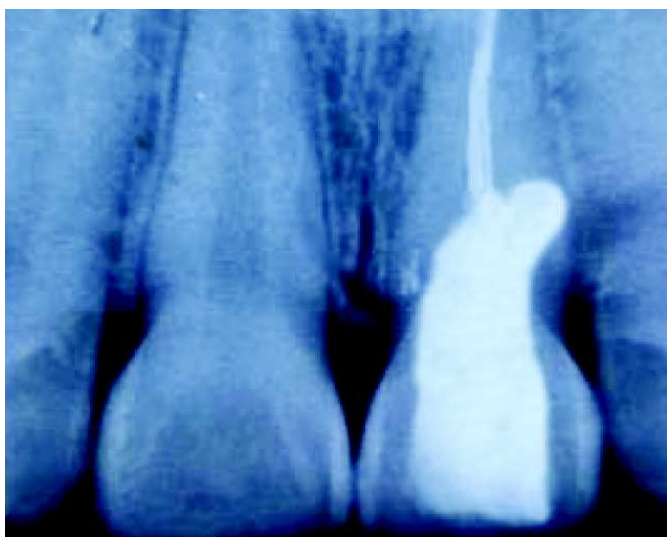


Figure 2 Post operative follow up with placement of mta (9 months)

REFERENCES

- Lee SJ, Monsef M, Torabinejad M. Sealing ability of a mineral trioxide aggregate for repair of lateral root perforations. *J Endod* 1993;19:541-544.
- Osorio RM, Hefti A, Vertucci FJ, Shawley AL. Cytotoxicity of endodontic materials. *J Endod* 1998;24:91-96.
- Qiang Zhu, Robert Haglund, Kamran E. Safavi, Larg S. W. Spanberg : Adhesion of Human Osteoblasts on Root-End Filling Materials. *J Endod* 2000;27:404-406.
- Ruddle CJ. Nonsurgical Endodontic Retreatment. In: Cohen S, Burns RC (eds). *Pathways of the pulp*, 8th ed. St Louis: Mosby Inc; 2002. p. 917.
- Sinai IH. Endodontic perforations: their prognosis and treatment. *J Am Dent Assoc* 1977;95:90–5.
- Seltzer S, Sinai I, August D. Periodontal effects of root perforations before and during endodontic procedures. *J Dent Res* 1970;49:332–9.
- Hirsch JM, Ahlstrom U, Henrikson PA, Heyden G, Peterson LE. Periapical surgery. *Int J Oral Surg* 1979;8:173–85.
- Torabinejad M, Hong CU, Lee SJ, Monsef M, Pitt Ford TR. Investigation of mineral trioxide aggregate for root-filling in dogs. *J Endod* 1995;21:603-608.
- Torabinejad M, Pitt Ford TR. Root-end filling materials: a review. *Endod Dent Traumatol* 1996;12:161-178.
- Torabinejad M, Pitt Ford TR, McKendry DJ, Abedi HR, Miller A, Kariyawasam SP. Histologic assessment of mineral trioxide aggregate as a root-end filling in monkeys. *J Endod* 1997;23:225-228.
- Wu M, Kontakiotis EG, Wesselink PR. Long-term seal provided by some root-end filling materials. *J Endod* 1998;24:557-560.
- Shabahang S, Torabinejad M, Boyne PP, Abedi H, McMillan P. A comparative study of root-end induction using osteogenic protein-1, calcium hydroxide and mineral trioxide aggregate in dogs. *J Endod* 1999;25:1-5.
- Bates CF, Carners DL, Del Rio CE. Longitudinal sealing ability of MTA as a root-end filling material. *J Endod* 1996;22:575-578.
- Keiser K, Johnson C, Tipton DA. Cytotoxicity of MTA using human periodontal ligament fibroblasts. *J Endod* 2000;26:288-289.
- Holland R, Filho JA, De Souza V, Nery MJ, Bernabe PF, Junior ED. Mineral trioxide aggregate repair of lateral root perforations. *J Endod* 2001;1:281–284.
- Yaltirik M, Ozbas H, Bilgic B, Issever H. Reactions of connective tissue to mineral trioxide aggregate and amalgam. *J Endod* 2004;30:95–99.
- Holland R, Otoboni Filho JA, De Souza V, Nery MJ, Bernabe PF, Dezan E. Mineral trioxide aggregate repair of lateral root perforations. *J Endod* 2001;27:281-4.
- Torabinejad M, Pitt Ford TR, McKendry DJ, Abedi HR, Miller DA, Kariyawasam SP. Histologic assessment of mineral trioxide aggregate as a root-end filling in monkeys. *J Endod* 1997;23:225-8.
- Menezes R, da Silva Neto UX, Carneiro E, Letra A, Bramante CM, Bernadinelli N. MTA repair of a supracrestal perforation: a case report. *J Endod* 2005;31:212-4.
- Arens DE, Torabinejad M. Repair of furcal perforations with mineral trioxide aggregate- two case reports. *Oral Surg Oral Med Oral Pathol Oral Radiol Endod* 1996;82:84-8.
- Hsien HC, Cheng YA, Lee YL, Lan WH, Lin CP. Repair of perforating internal resorption with mineral trioxide aggregate: a case report. *J Endod* 2003;29:538-9.
- Main C, Mirzayan N, Shabahang S, Torabinejad M. Repair of root perforations using mineral trioxide aggregate: a long term study. *J Endod* 2004;30:80-3.