

## CASE REPORT

# An unusual case of cardiac tamponade due to rupture of ascending aorta in a young adult

*DebBarma Antara<sup>1</sup>, Yadav Abhishek<sup>2</sup>, Kanwar HK<sup>3</sup>, Dey Arjit<sup>4</sup>, Gupta SK<sup>5</sup>*

*Received on March 01, 2018; editorial approval on June 07, 2018*

### ABSTRACT

*Cardiovascular Diseases (CVD) are very prevalent in India and above 20 years, the estimated prevalence is 3-4% in rural and 8-10% in urban. The most common cause of sudden cardiac death among young adults is hypertrophic cardiomyopathy followed by coronary ar-tery anomalies. We report one case of sudden cardiac death due to cardiac tamponade consequent upon ruptured ascending aorta in a young adult male. The deceased had left ventricular hypertrophy suggesting the presence of chronic hypertension. He did not have any previous complaints prior to his death, any history of genetic disorder and particularly no family history of hypertension in the family. The interview with the relatives revealed that the deceased used to do regular gymnasium exercise and might have been using muscle building protein supplements. This can be considered as a predisposing factor for his pathological Heart condition and untimely death. The authors want to highlight the importance of regular health check-up for cardiac diseases even in unsuspecting healthy individuals.*

**Keywords:** Hemopericardium, Hypertrophic Cardiomyopathy, Hypertension

### INTRODUCTION

Cardiovascular diseases (CVD) are very prevalent in India and above 20 years, the estimated prevalence is 3-4% in rural and 8-10% in urban.<sup>1</sup>The cardiac causes are the most common causes of sudden death.<sup>2</sup>Sudden cardiac deaths are getting frequently reported in young adults in Medical Literature. Such untimely and unexpected deaths are not only a great emotional loss to family members but also to a Nation's productivity. The most common causes of sudden cardiac death among young adults, in descending order of frequency, are hypertrophic cardiomyopathy, coronary ar-tery anomalies with an inter-arterial or intramural course, and arrhythmogenic right ventricular car-diomyopathy (ARVC).<sup>3,4</sup>Health

professionals spread awareness about the importance of cardiac health and recommends regular health checkups, but still this aspect is very often being overlooked by the people particularly in the young age groups and the risk continues to rise in Indian Population.<sup>1</sup>We report one unusual case of sudden cardiac death in a healthy youth due to ruptured ascending aorta leading to Hemopericardium(HP) cardiac tamponade (CT).

### CASE HISTORY

The deceased was a young adult male of 25 years and belonged to an affluent family with a rich modern life style. On the day of the incident, he went along with a group of his friends to watch movie in a multiplex movie theatre. There he sat comfortably inside the hall at his allotted seat, but soon after his friends found him in an unconscious condition in his seat. They rushed him to a hospital, where he was declared brought dead. The dead body of the deceased was then brought to the Department of Forensic Medicine, All India Institute of Medical Sciences, New Delhi for post mortem examination. There was no history of any significant illness nor did his friends report any complaints previous to his death.

### AUTOPSY FINDINGS

The deceased was of heavy and muscular built. Face was congested. No external injuries were present over the body on external examination.

Lungs were edematous and congested. Brain was congested and edematous. On opening the pericardial sac, about 300 ml

---

#### Address for correspondence:

<sup>1</sup>Senior Resident (**Corresponding author**)

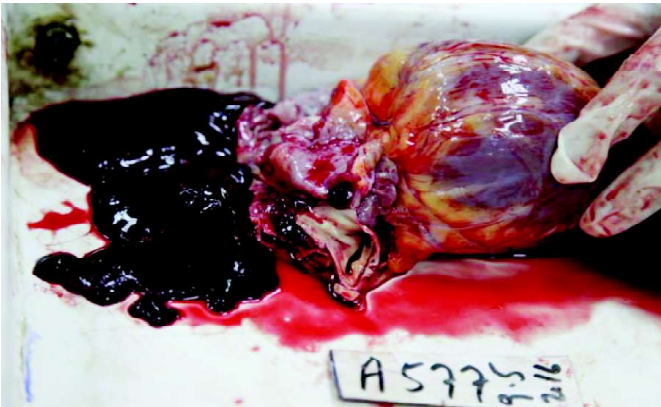**Email:** antaradebbbarma@gmail.com

**Mobile:** +919205623401

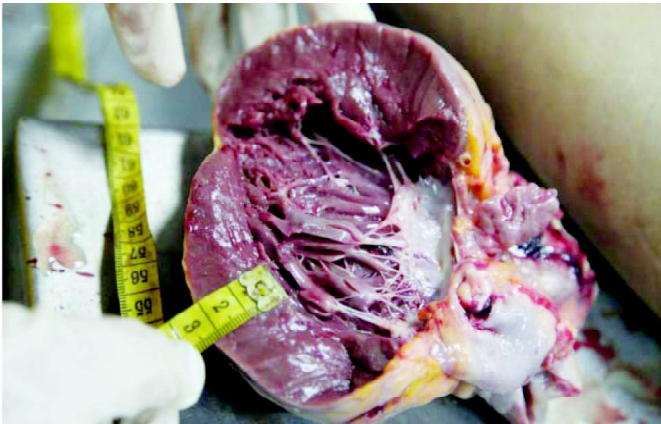<sup>2</sup>Assistant Professor, <sup>3,4</sup>Senior Resident, <sup>5</sup>Professor & Head  
Department of Forensic Medicine and Toxicology  
AIIMS, New Delhi-110029

**Cite this article as:** Deb Barma Antara, Yadav Abhishek, Kanwar HK, Dey Arjit, Gupta SK. An unusual case of cardiac tamponade due to rupture of ascending aorta in a young adult. *Int J Health Res Medico Leg Prae* 2018 July;4(2):105-107. DOI 10.31741/ijhrmlp.v4.i2.2018.26

of liquid and clotted blood was present in pericardial cavity and was partially organized over the ventricles (**Figure 1**).

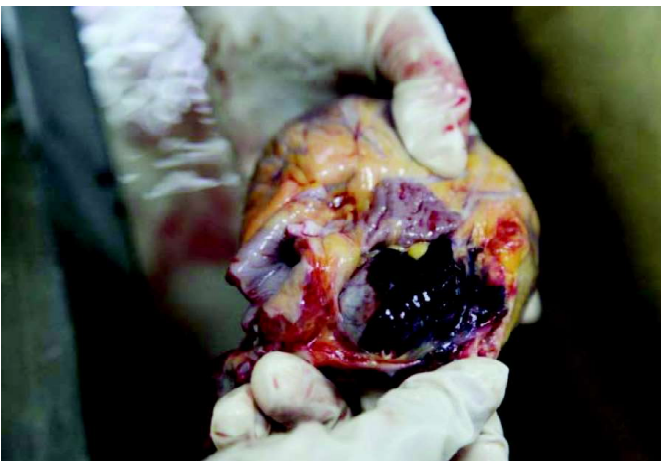


**Figure 1** Liquid and Clotted blood present in Pericardial Cavity Heart was enlarged weighing 440 gms. Left ventricle hypertrophy was present with a thickness of 2.4cm (**Figure 2**).



**Figure 2** Left Ventricular hypertrophy

Rupture was present in Postero-lateral wall of ascending aorta just away from its origin (**Figure3**). Hyperemic area was present around the rupture site. Multiple petechiae were present over the Epicardial surface of the ventricles.



**Figure 3** Tear in the Postero-lateral wall of Ascending Aorta

Stomach contained about 50 ml semi-digested yellowish fluid with no specific smell and normal mucosal walls. Liver, spleen, and Kidneys were congested. No abnormality was detected in the Pelvic cavity, Pelvic bones and Bladder.

#### HISTOPATHOLOGICAL EXAMINATION

HPE examination showed infiltration of the neutrophils in the ruptured site, suggesting of antemortem tear. No changes were seen in the left ventricular wall. On HPE of lungs, pulmonary macrophages were present, which suggested of heart failure.

#### TOXICOLOGICAL ANALYSIS REPORT

Toxicological analysis report came negative for all common poisons and alcohol.

#### DISCUSSION

Hemopericardium (HP), which is filling of blood in the pericardial cavity leads to the clinical state of cardiac tamponade (CT)<sup>5</sup> which is fatal enough to cause sudden death in undiagnosed conditions. The volume of blood necessary to produce CT may be about 200 ml in cases where rupture is bigger and there is sudden and rapid leakage of blood into the pericardium or may be greater than 2000ml in cases where rupture is smaller and there is slow leakage of blood into the pericardium. The filling of blood limits the expanding of heart in diastole. This leads to incomplete filling of ventricles and great vessels ultimately resulting in low stroke volume<sup>5,6</sup> and causing sudden death. In our case there was 300 ml of blood in the pericardial cavity which is sufficient to cause sudden death of the deceased.

HP following trauma to the chest develop due to tear in the ventricles, rupture of ascending aorta, pericardial vessel or coronary artery.<sup>5,7,8</sup> In non-traumatic causes, Swaminathan reported that incidence of HP due to the rupture of acute MI to be the most common (69% cases).<sup>9</sup> In non-arrhythmic complications of MI ventricular wall rupture is second most common cause of death, first being cardiogenic shock.<sup>10</sup> Though the rupture of the heart is the most common cause of HP leading to CT<sup>6</sup>, but, in our case, we have diagnosed a rare case of CT due to ruptured ascending aorta. The histopathological findings of the lungs further confirmed consequent Heart failure. CT may develop rapidly and leads to sudden death or it may develop slowly with the clinical symptoms resembling heart failure like dyspnea, orthopnea and hepatic engorgement<sup>5</sup> The diagnosis is confirmed by Beck's triad i.e. hypotension, soft or absent heart sounds and Jugular venous distension with a prominent X descent but an absent Y descent. Paradoxical pulse is a vital clue to the diagnosis of CT.<sup>3</sup> Echocardiography further confirms the diagnosis.<sup>11</sup>

Detailed interview with the relatives revealed that there was no specific history of hypertension, genetic disorder in the family, any cardiac complaints or trauma prior to the incident. The deceased used to do regular gymnasium exercises and though the family members were not sure but they stated that he might have been possibly using protein or other muscle

enhancing supplements. The strenuous gymnasium exercises particularly for muscle building involves increased cardiac output and increased blood flow into the arterial system. This enhanced blood flow can cause continuous damage to the intima of aorta and predisposing it for rupture. Moreover, the deceased had findings consistent with hypertension i.e. left ventricular hypertrophy and enlargement of heart, which also leads to high cardiac output. Various studies in the past have also advocated for screening of young individuals particularly those involved in athletics and exercise.<sup>12,13</sup> Such screenings have identified the young athletes with increased risk of cardiovascular diseases thereby decreasing incidence of sudden deaths.<sup>14,15</sup>

### CONCLUSION

More and more of sudden cardiac death cases are being reported in young adults, giving a hint towards a luxury life style being the predisposing factor particularly junk foods, alcohol abuse, smoking, stress factor, lack of daily exercise or unsupervised heavy exercise.. The protein or muscle building supplements should be taken only under Medical supervision and regular health checkups should be done in such cases. The Forensic pathologist should take into consideration the natural causes of Hemopericardium by considering the factors like history of past illness/genetic disorder or absence of injuries

### ABBREVIATIONS

CVD-Cardiovascular Disease

CT – Cardiac Tamponade

HP – Haemopericardium

MI –Myocardial Infarction

**Acknowledgements:** Nil

**Conflict of interests:** None.

**Source of funding:** Self.

**Ethical clearance:** Not required.

### REFERNCES

1. Ajay VS, Prabhakaran D. Coronary heart disease in Indians: Implications of the interheart study. *Indian J Med Res* 2010;132:561-66.
2. Libby P. The pathogenesis, prevention, and treatment of atherosclerosis. In: Longo DL, Fauci AS, Kasper DL, Hauser SL, Jameson JL, Loscalzo J. *Harrison's principles of internal medicine*, vol-2, 18<sup>th</sup> ed. Chapter241. USA: The McGraw Hill; 2011.p. 1983.
3. Zipes DP, Camm AJ, Borggreffe M, Buxton AE et al. Guidelines for Management of Patients With Ventricular Arrhythmias and the Pre-vention of Sudden Cardiac Death: a report of the American College of Cardiology/ American Heart Association Task Force and the European Society of Cardiology Committee for Practice Guidelines. *Circulation* 2006;114(10):385–484.
4. Sen-Chowdhry S, McKenna WJ. Sudden cardiac death in the young: a strategy for prevention by tar-geted evaluation. *Cardiology* 2006;105(4):196–206.
5. Braunwald E. Pericardial Diseases. In: Longo DL, Fauci AS, Kasper DL, Hauser SL, Jameson JL, Loscalzo J. *Harrison's Principles of Internal Medicine*, vol-2, 18<sup>th</sup>ed. Chapter239. USA: The Mc Graw Hill; 1972. p. 74.
6. Knight B, Saukko P. *Knight's Forensic Pathology*, 3<sup>rd</sup> ed. London: Arnold; 2004. p.502.
7. Altuna G, Altunb A, Yilmaza A. Hemopericardium-Related Fatalities: A 10-Year Medicolegal Autopsy Experience. *Cardiology* 2005;104:133-7.
8. Mathur I, Bohra B, Sharma KD, Nag J, Saini OP, Q Fatima. Cardiac amponade: A Small case series. *JIAFM* 2011;33(3):277-9.
9. Swaminathan A, Kandaswamy K, Powari M, Mathew J. Dying from cardiac tamponade. *World Jr of Em Sur* 2007;2:22.
10. Prieto A, Eisenberg J, Thakur RK. Nonarrhythmic Complications of acute Myocardial Infarction. *Emerg Med Clin Nor Am*2001;19(2):397-415.
11. Figueras J, Cortadellas J, Soler-Soler J. Left ventricular free wall rupture: clinical presentation and management. *Heart [Internet]* 2000 [Cited 2015 Jan 07];83:499–504. Available From: URL:<http://heart.bmj.com/content/83/5/499.full>
12. Marek JC, Marek SA, Marek KA, Zimmerman F, Davis J.A novel approach to screening for sudden cardiac death in young adults utilizing a Stratified method with ECG and Echo. *JACC* 2010;55.
13. Asif IM, Drezner JA. Sudden cardiac death and pre-participation screening: the debate continues—in support of electrocardiogram-inclusive pre-participa-tion screening. *Prog Cardiovasc Dis* 2012;54(5):445–50.
14. Corrado D, Basso C, Pavei A, Michieli P, Schiavon M, ThieneG.Trends in sudden cardiovascular death in young competitive athletesafter implementation of a pre-participation screening program. *JAMA*2006; 296:1593-1601.
15. Corrado D, Basso C, Schiavon M, Thiene G. Screening for hypertrophiccardiomyopathy in young athletes. *N Engl J Med* 1998;339:364-9.