

CASE ARTICLE

Unusual Case of Vesicocutaneous Fistula-our Experience

TP Rajeev¹, Baishya Debajit², Baruah Sasanka Kumar³, Sarma Debanga⁴

Received on June 27, 2015; Accepted (revised) on August 27, 2015

ABSTRACT

A rare case of vesicocutaneous fistula due to spontaneous expulsion of large vesical calculi is described. A 55-year-old woman suffered from continuous urinary leakage from a lower abdominal ulcer for the last 20 years after a history of spontaneous expulsion of stones from the lower abdomen. CT-IVU done revealed breach in linea alba below umbilicus for a length of 9 x 6.3 cm. Anterior bladder wall was absent at the fundus with contrast extravasation through the fistulous tract. We performed bladder closure with augmentation cystoplasty with terminal ileum along with meshplasty of the abdominal wall. Worldwide, vesical stone expulsion through a large vesicocutaneous fistula is extremely rare and no case has been reported till date.

Keywords: Vesical calculus, infection, augmentation cystoplasty, meshplasty

Address for Correspondence and reprint:

¹Professor and Head (Corresponding Author)

Mobile: 98640 64374

Email: guwa1986@gmail.com

²M.Ch trainee,

Mobile: 9859137883

Email: drdebajitbaishya@gmail.com

³Associate Professor

Mobile: 9864096583

Email: sasankagmch@gmail.com

⁴Assistant Professor

Mobile: 9435049201

Email: debangasarma@gmail.com

Department of Urology, Gauhati Medical College and Hospital,, Guwahati, Assam

INTRODUCTION

Bladder stones are the most common manifestation of lower urinary tract lithiasis, accounting for 5% of all urinary stone disease and approximately 1.5% of all urologic hospital admissions.¹ Men are affected eight times more frequently than women.² Primary bladder stones develop in the absence of any known functional, anatomic or infectious factors and do not necessarily imply that stones have formed de novo in the bladder.³ Peak incidence is at 2 to 4 years of age.^{4,5} Stones are usually solitary and once removed, rarely recur. Secondary bladder calculi typically found in men older than the age of 60 and usually in concert with lower urinary tract obstruction, intravesical foreign body, neurogenic bladder and spinal cord injury.^{6,7} Giant vesical calculi of more than 100g are rare in recent urological practice. Very few reports are available in literature having weight of vesical stone more than 100g.⁸ Vesical stone expulsion through a large vesicocutaneous fistula is extremely rare and no case has been reported till date.

CASE HISTORY

A 55 year old female came with a history of urinary leakage from a lower abdominal ulcer for the last 20 years. This was preceded with lower abdominal pain, fever with chill and rigor which progressed to thinning and reddening of lower abdominal skin, sudden burst out of lower abdomen with expulsion of 5-6 large calculi of the size of a potato, following which she was relieved of her symptoms but left behind an ulcer over the lower abdomen through which urine leaked continuously.

Per abdominal examination revealed a midline ulcer of 5 x 8 cm in the infra umbilical region. It was pale red in colour and thick, but does not bleed on touch (**Figure 1**).

The opening of the ulcer was deep into the pelvis and urine comes out continuously from the opening. The ulcer becomes larger and more prominent when the patient stood up. On catheterization the urethral catheter comes out through the defect in the lower abdomen.

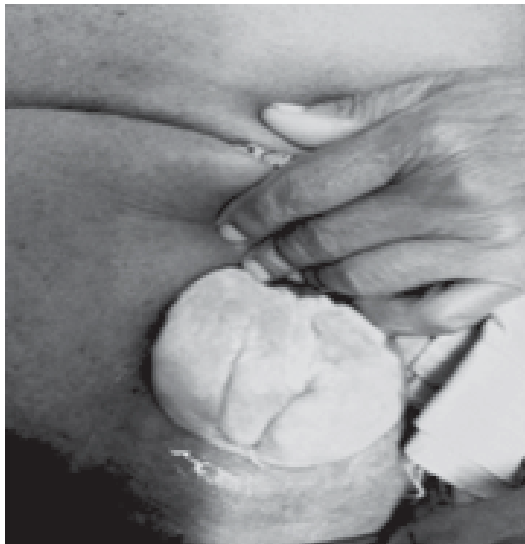

Figure 1 Large Vesicocutaneous Fistula

CT-IVU done revealed divarification of recti along with breach in linea alba below umbilicus for a length of 9 x 6.3 cm. Anterior bladder wall is absent at the fundus. There is contrast extravasation through the fistulous tract (**Figure 2**).

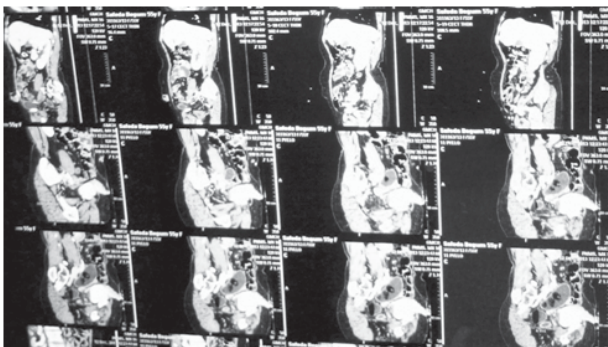


Figure 2 CECT whole abdomen showing anterior abdominal wall defect and contrast extravasation seen through the defect

Urine culture was sterile and preoperative bladder biopsy showed increase collagen in the bladder wall. Bladder closure with augmentation cystoplasty with terminal ileum (**Figure 3**) along with meshplasty of the abdominal wall was done (**Figure 4**).

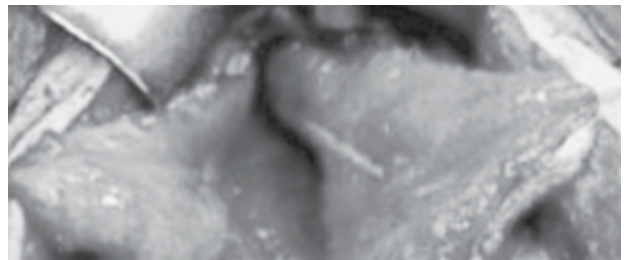


Figure 3 Intraoperative picture showing thick bladder wall

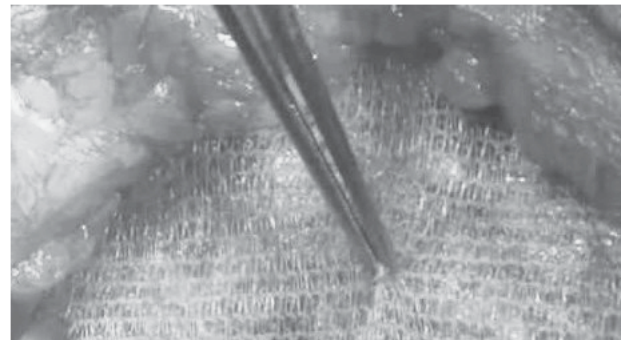


Figure 4 Abdominal wall meshplasty

DISCUSSION

Bladder stones are the most common manifestation of lower urinary tract lithiasis, accounting for 5% of all urinary stone disease.¹ Bladder calculi in nonendemic areas are typically found in adults and almost always in association with other disease processes resulting in urinary stasis or the introduction of a foreign body. However, in endemic regions, bladder calculi often arise in children in whom a major anatomic abnormality does not coexist; in these regions, dietary intake and socioeconomic factors primarily influence the formation of bladder calculi. Vesicocutaneous fistula, a very distressing condition has a tremendous impact on the quality of life of the patient.⁹ The constant leakage of urine results in maceration and eventual destruction of skin with ensuing infection, discomfort and malodour. With proper investigations and adequate surgical treatment it can be corrected and life threatening complication like malignancy and sepsis can be prevented.¹⁰ A fistula is an abnormal communication between two epithelially lined surfaces.¹¹ Vesicocutaneous fistula is an external fistula; it may be congenital or acquired type. Acquired fistula occurs after operations on the urinary bladder, after accidental injury to bladder and in malignancy.¹² Internal fistula formation is most commonly due to malignant and inflammatory condition of surrounding viscera.¹³ Patients with vesical calculi

usually presented with vague abdominal discomfort, dysuria, frequency, hematuria and urinary retention. Vesicocutaneous fistula formation due to vesical calculus is extremely a rare occurrence.¹⁴ The rectus abdominal muscles make it difficult for a fistula to form in that area. Small bladder stone cause bladder irritation, so patients take immediate medical advice. Long standing vesical calculi may grow to a certain size without causing many symptoms. Again patients' reluctance or lack of awareness for medical advice can cause the above mentioned problem.¹⁵ In our case, the patient belonged to a poor backward family and had not taken medical advice due to ignorance. Large vesical stones with chronically inflamed bladder with chronic cystitis sometimes cause acute urinary obstruction and along with suppuration cause pyocystitis which can induce erosion and subsequent fistula formation.

X-ray KUB is helpful in diagnosing vesical stone. CT-IVU is very beneficial for the diagnosis of vesicocutaneous fistula due to vesical calculus.

CONCLUSION

Vesical stone expulsion through a large vesicocutaneous fistula is extremely rare. Management of vesicocutaneous fistula with giant vesical calculus is essentially surgical. In addition to the treatment of fistula the primary condition leading to fistula formation must be treated simultaneously. Though extremely rare the possibility of giant vesical calculus should always be considered while investigating a case of vesicocutaneous fistula.

Conflict of interest: None declared.

Contribution of authors: We declare that this work was done by authors named in this article and all liabilities pertaining to claims relating to the content of this article will be borne by the authors.

REFERENCES

- Schwartz BF, Stoller ML. The vesical calculus. *Urol Clin North Am.* 2000;27:333.
- Neal DE. The urinary bladder. *Bailey and Love's short practice of surgery.* London: Hodder Arnold. 2008. p. 1323–1324.
- Andersen, DA. The nutritional significance of primary bladder stone. *Br. J. Urol.*, 1962;34:160.
- Thalut K., Rizal A., Brockis J.G., Bowyer, R.C., Taylor, T.A. and Wisniewski, Z.W. The endemic bladder stones of Indonesia; epidemiology and clinical features. *Br. J. Urol.* 1976; 48:6 17.
- Valyasevi, A. and Van Reen, R. Pediatric bladder stone disease; current status of research. *J. Pediatr.* 1968;72:546.
- Douenias R, Rich M, Badiani G, et al. Predisposing factors in bladder calculi: review of 100 cases. *Urology.* 1991;37:240-245.
- Hesse A, Siener R: Current aspects of epidemiology and nutrition in urinary stone disease. *World J Urol.* 1997;15:165-171.
- Gupta Shilpi, Singh Onkar, Shukla Sumit, K Mathur Raj. Giant vesical calculus. *Internet J Surg,* 2008;17(1)
- Toufique H, Merani AJ, Vesicocutaneous fistula *J Pak Med Assoc.* 2011. Sep;61(9):918-9
- Kishore TA, Bhat S, Jhon PR. Vesicocutaneous fistula arising from a bladder diverticulum. *Indian J Med Sci* 2005;59: 265-7
- Greenbaum AR, Chan CLH. Skin and subcutaneous tissue. *Bailey and Love's short practice of surgery.* London: Hodder Arnold; 2008. p. 596.
- Lau KO, Cheng C. A case report. Delayed vesicocutaneous fistula after radiation therapy for advanced vulvar cancer. *Ann Acad Med Singapor* 1998;27:705-6.
- Tanagho EA. Disorders of the bladder, prostate, & seminal vesicles. *Smith's General Urology.* New York: McGraw Hill; 2008. p. 581.
- Kobori Y, Shigehara K, Amano T, Takemae K. Vesicocutaneous fistula caused by giant Vesical calculus. *Urol Res.* 2007; 35 (3):161–163.
- Castillo de Lira HH, Chavez Martinez VH, Velazquez Macias R, Hernandez C, Landa Soler M. Vesicocutaneous fistula secondary to giant vesical calculus. *Rev Mex Urol.* 2008; 68(3):183–185.