

## CASE REPORT

# Sudden death during liposuction surgery: a rare occurrence

DebBarma Antara<sup>1</sup>, Dey Arijit<sup>2</sup>, Yadav Abhishek<sup>3</sup>, Prasad Kulbhushan<sup>4</sup>, Gupta SK<sup>5</sup>

Received on April 24, 2019; editorial approval on June 10, 2019

## ABSTRACT

Liposuction is a cosmetic surgery which is gaining popularity in present day modern world. This procedure is considered to be safe and very rarely leads to fatality. The authors report a rare case of Intra-operative death due to fat embolism during liposuction operation. The deceased had minimal pre-diagnosed risk factors for developing the complication while undergoing abdominal liposuction. Autopsy revealed hematoma over pericardium with luminal blockade of all coronary vessels. Hematoma and fat coagulum mixed masses were spread in between the peritoneal wall and subcutaneous tissue and. Histopathology examination of lungs and brain were done where fat embolism was present in lungs and meningeal vessels. Fat embolism syndrome (FES) is a life-threatening condition which has been described in patients after liposuction both mechanically and biochemically. Sudden deaths in a surgical procedure such as liposuction can easily lead to allegations of medical negligence. A thorough autopsy, along with histopathological examination can reveal the actual cause of death, as evident in this case. The authors aim to increase the awareness of public and Medical profession regarding the fatal complication of aesthetic procedures which are considered generally harmless.

**Keywords:** Fat embolism syndrome; Pulmonary fat embolism; Cosmetic Surgery.

## INTRODUCTION

Liposuction is a surgical technique that improves the body's contour by removing excess fat deposits located between the skin and muscle and is a commonly performed aesthetic procedure.<sup>1</sup> Although it is considered as a procedure with few clinical side effects, the increasing popularity of liposuction brings more frequent reports of related complications. According to an American Society for Aesthetic Plastic Surgery survey,<sup>2</sup> the complication rate per 100,000 liposuctions performed by plastic surgery specialists

is 0.25%, while the mortality rate is 0.002%. Fat embolism is one of the most serious complications in liposuction. It can result from cosmetic surgery such as liposuction and/or fat grafting, cardiopulmonary bypass, pancreatitis, joint repair, severe burns, sickle cell anemia, diabetes mellitus, and lipid parenteral infusion.<sup>3,4</sup> The overall mortality from FES after liposuction is approximately 10–15%<sup>5</sup> with higher mortality associated with fulminant FES due to severe right heart failure compared with FES in which the mortality relates largely to underlying respiratory failure (or rarely cerebral edema causing brain death).<sup>6</sup> We report a case of a fatal outcome of a massive fat embolism in a young individual during the intra-operative period of an abdominal liposuction resulting in embolic stroke and sudden death. The authors aim to increase the awareness of public and medical profession regarding the fatal complication of aesthetic procedures which are considered generally harmless.

## Case history

A 34 year old male with body weight 94 kg and BMI 32.2 kg/m<sup>2</sup> with history of hypothyroidism was admitted to a hospital with diagnosis of resistant abdominal fat, to undergo liposuction from abdomen, back and face. Prior to the operation, a detailed informed consent was taken, where risk of fat embolism was mentioned. Pre operative Anesthetic check-up was done, which included routine blood tests, Echocardiography, chest X ray, ECG and all were within normal limits. During operation, under General Anesthesia,

---

## Address for correspondence:

<sup>1</sup>Senior Medical Officer (**Corresponding author**)

**Email:** antaradebbbarma@gmail.com

**Mobile:** +919205623401

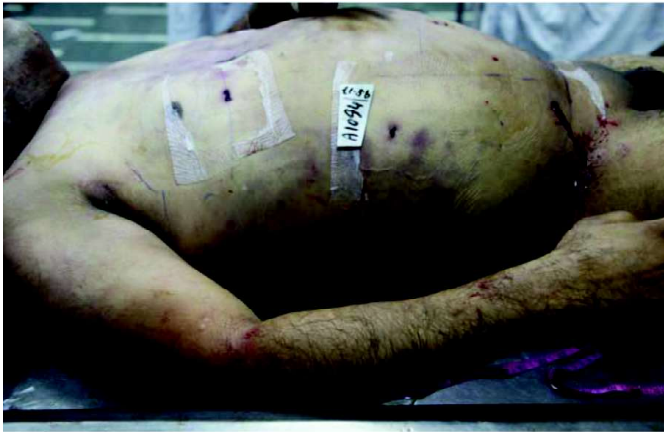<sup>2</sup>Senior Resident, <sup>3</sup>Assistant Professor, <sup>4</sup>Professor & Head Department of Forensic Medicine and Toxicology, All India Institute of Medical Sciences (AIIMS), New Delhi-110029

**Cite this article as:** DebBarma Antara, Dey Arijit, Yadav Abhishek, Prasad Kulbhushan, Gupta SK. Sudden death during liposuction surgery: a rare occurrence. *Int J Health Res Medico Leg Prae* 2019 July;5(2):80-82. DOI 10.31741/ijhrmlp.v5.i2.2019.18

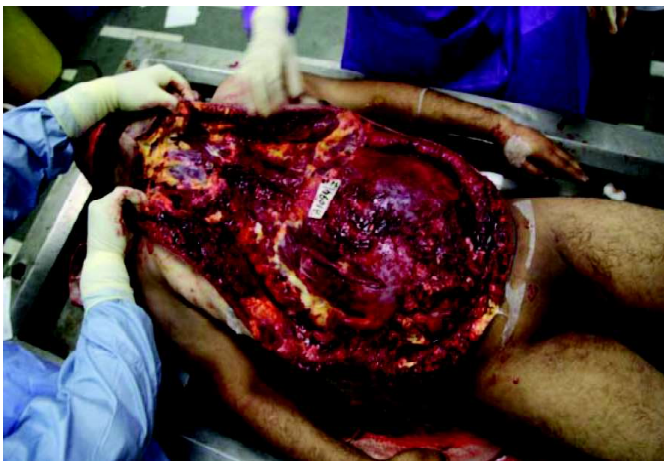3.5 liters of tumescent was injected and abdominal liposuction done on the abdomen, back and flanks and around 4.5 liters of fat was removed. At the end of liposuction operation, patient started de-saturating, became unconscious suddenly and suffered a cardiac arrest immediately. Patient was transferred to a nearby super specialty hospital, where he was declared to be brought dead.

### Autopsy findings

Autopsy was performed in Department of Forensic Medicine, All India Institute of Medical Sciences (AIIMS), New Delhi. There were surgical bandages present over lower part of face, right flank, both gluteal regions, lower part of anterior chest and abdominal walls. Multiple surgically created punctured wounds were present below both nipples, just above umbilicus, bilaterally over inguinal area and over both flanks (Figure 1).



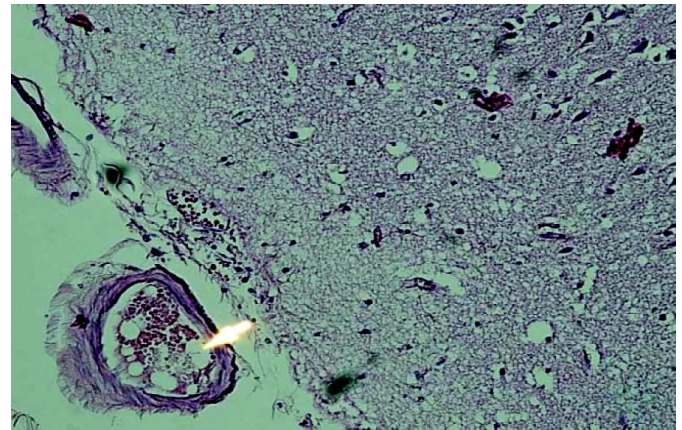
**Figure 1** Multiple surgically created punctured wounds were present below both nipples, just above umbilicus, bilaterally over inguinal area and over both flanks.



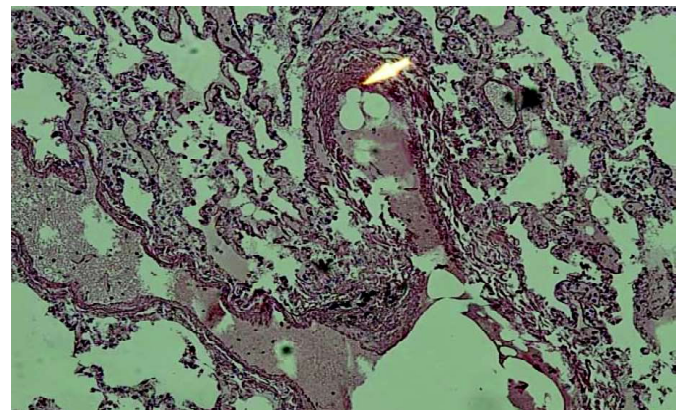
**Figure 2** Subcutaneous fat of thoracic and peritoneal cavity was turned into hemorrhagic and fibrotic mass

Subcutaneous fat of thoracic and peritoneal cavity was turned into hemorrhagic and fibrotic mass (Figure-2). Liver was enlarged, with hepatic steatosis. Heart showed 90% stenosis of left anterior descending and right circumflex artery along

with a haematoma over pericardium. Histopathology revealed mild edema of brain parenchyma and fat embolus in meningeal vessels. Pulmonary alveolar spaces were partially collapsed and fat embolus was present in pulmonary blood vessels (Figure 3 and 4). The cause of death was opined as cerebral and pulmonary embolism during liposuction operation.



**Figure 3** Histopathology confirms fat embolus present in cerebral blood vessels.



**Figure 4** Histopathology confirms fat embolus present in pulmonary blood vessels.

### DISCUSSION

Liposuction is a very common cosmetic surgical procedure nowadays that consists of removal of excess fatty tissue from healthy bodies, done under general or local anesthesia according to the extent of the area to be treated.<sup>7</sup> Intervention may be performed using various surgical techniques: Wetting solution techniques, standard liposuction or suction-assisted lipoplasty, internal ultrasound-assisted liposuction, VASSER-assisted liposuction, external ultrasound-assisted liposuction, LASER-assisted liposuction, power-assisted liposuction and Vibro liposuction.<sup>8</sup> Minor complications following liposuction include seroma, hematoma, hyper-pigmentation and penile or vulvar swelling. The serious major complications include sepsis,<sup>9</sup> perforation of abdominal or thoracic viscera,<sup>10,11</sup> hemorrhage, hypotension,<sup>12</sup> pulmonary embolism,<sup>13</sup> fat embolism,<sup>14</sup> pulmonary edema and cardiac arrest<sup>15</sup>. In the case reported here, the plastic surgery hospital used the

wetting solution technique in liposuction, which destroys the cytomembrane of the subcutaneous fat cell using the injection of isotonic or hypotonic normal saline into the operative site prior to liposuction. The level of surgical influence on the body is directly relative to the fat suction volume, surgical scope, and patient's general condition. Large volume and multi-position liposuction causes pulmonary and cerebral embolism, postoperative infection, and left lower limb deep venous thrombosis. If the fat tissue is badly damaged and surpasses the ability of plasma to decompose, substantial amounts of free fat enter the blood and cause Fat Embolism Syndrome (FES), which is the most significant complication causing mortality in liposuction.<sup>16</sup>

There is no specific therapy for FES, so prevention, early diagnosis, and supportive therapies are very important. Prevention of FES should include careful selection of patients and techniques, reduction of surgical time and the amount of fat aspirated and postoperative close observation and patient monitoring with intravenous fluid treatment for a minimum of 24 hour postoperatively.<sup>17,18</sup> FES is a self-limiting disease with respiratory distress, so therapeutic measures are aimed at improving respiratory conditions during the disease. Low-molecular-weight dextran is helpful to decrease blood viscosity, reduce platelet adhesion, reverse thrombocytopenia and reduce cell aggregation. Also, steroids are used extensively, as they limit the increase of FFAs, diminish the inflammatory response, inhibit complement-mediated leukocyte aggregation, protect capillary integrity and minimize interstitial edema accumulation.

### CONCLUSION

FES occurring in surgical liposuction can be rapidly fatal as evident from this case. The Surgeons and Anesthesiologists should be aware and prepared for early diagnosis and treatment. Minimum conditions of operation theatre infrastructure and ICU backup required should be ensured for unforeseen complications. Surgical aesthetic procedures should preferably be performed in Tertiary care hospitals with optimum diagnostic and therapeutic resources in cases of such operative complications.

**Conflict of Interest:** None declared.

**Funding:** None.

### REFERENCES

1. Fodor PB. Reflections on Lipoplasty: History and personal experience. *Aesthet Surg J* 2009;29:226-31.
2. Hughes CE. Reduction of lipoplasty risks and mortality: An ASAPS survey. *Aesthet Surg J* 2001;21:120-7.
3. Gurd A. Fat embolism: an aid to diagnosis. *J Bone Joint Surg* 1970;52:732-7.
4. Filomeno LTB, Carelli CR, Silva NCLF. Fat embolism: a review for current orthopaedics practice. *Acta Ortop Bras.* 2005;13:196-208.
5. Fulde GW, Harrison P. Fat embolism– a review. *Arch Emerg Med* 1991;8:233-9.
6. Glover P, Worthley LIG. Fat embolism. *Crit Care Resusc* 1991;1:226-74.
7. Regatieri FL, Mosquera MS. Liposuction anesthesia techniques. *Cli Plast Surg* 2006;33:27-37.
8. Mann MW, Palm MD, Sengelmann RD. New advances in liposuction technology. *Semin Cutan Med Surg* 2008;27:72-82.
9. Grazer FM, de Jong RH. Fatal outcomes from liposuction: Census survey of cosmetic surgeons. *Plast Reconstr Surg* 2000;105:436-48.
10. Sharma D, Dalencourt G, Bitterly T, Benotti PN. Small intestinal perforation and necrotizing fasciitis after abdominal liposuction. *Aesthetic Plast Surg* 2006;30:712-6.
11. Mallappa M, Rangaswamy M, Badiuddin MF. Small intestinal perforation and peritonitis after liposuction. *Aesthetic Plast Surg* 2007;31:589-92.
12. Rao RB, Ely SF, Hoffman RS. Deaths related to liposuction. *N Engl J Med* 1999;340:1471-5.
13. Triana L, Triana C, Barbato C, Zambrano M. Liposuction: 25 years of experience in 26,259 patients using different devices. *Aesthet Surg J* 2009;29:509-12.
14. Lehnhardt M, Homann HH, Daigeler A, Hauser J, Palka P, Steinau HU. Major and lethal complications of liposuction: A review of 72 cases in Germany between 1998 and 2002. *Plast Reconstr Surg* 2008;121:396e-403e.
15. Chaouat M, Levan P, Lalanne B, Buisson T, Nicolau P, Mimoun M. Abdominal dermolipectomies: Early postoperative complications and long-term unfavorable results. *Plast Reconstr Surg* 2000;106:1614-23.
16. Albin R, de Campo T. Large volume liposuction in 181 patients. *Aesthetic Plast Surg* 1999;23:5-15.
17. Kamal M, Ali El . Assessment of the risk of systemic fat mobilization and fat embolism as a consequence of liposuction: ex vivo study. *Plast Reconstr Surg* 117(7):2269-76.
18. Cardenas CL. Lipoaspiration and its complications- a safe operation. *Plast Reconstr Surg* 112(5):1435-41.

