

CASE REPORT

Endodontic management of type II dens invaginatus: a case report

Yaduka Pallavi¹, Katakhi Rubi², Angami Neingutunuo³

Received on May 05, 2019; editorial approval on June 25, 2019

ABSTRACT

Dens Invaginatus is a rare developmental anomaly that occurs due to invagination of enamel organ. Due to its complex anatomy, it often leads to early involvement of the pulp. Its aberrant anatomy poses a challenge to the dentists in cleaning and shaping of the root canal and subsequent obturation. Knowledge of root canal morphology and its anomalies are important for the success of endodontic treatment. Advanced imaging techniques like Cone Beam Computed Tomography offer the advantage of detailed 3D imaging and are helpful in treatment planning compared to conventional radiographs. This article presents a case report on endodontic management of Type II Dens invaginatus.

Keywords: Dens in dente, tooth anomalies, developmental anomalies, CBCT.

INTRODUCTION

Complexities in root canal anatomy pose a challenge to the clinician in diagnosis and treatment. Dens invaginatus (DI), also known as Dens in dente, invaginated odontoma or dilated composite odontoma is a rare developmental anomaly resulting from deepening or invagination of the enamel organ into the dental papilla prior to calcification of the dental tissues.¹ It was first described as “a tooth within a tooth” by Salter in 1855 and was first described by Socrates in human tooth in 1856.²

The prevalence of Dens invaginatus ranges from 0.04 to 10%. The permanent dentition is more commonly affected than the deciduous dentition.³ The teeth most affected are the maxillary lateral incisors (prevalence of 0.25–5.1%), frequently bilateral (43%), followed by central incisors, canines, premolars, and molars. Both maxillary and mandibular teeth are affected but mandibular occurrence of this anomaly is rare.⁴

Different classifications have been given by authors. The most common classification proposed by Oehler,⁵ classifies DI into three categories according to the communication with periapical tissues and the depth of penetration. Type I is enamel-lined minor invagination occurring within the crown without extending beyond the cemento-enamel junction. Type II is enamel-lined invagination extending into the root beyond the cemento-enamel junction, remaining as a blind sac. Type III is invagination penetrating through the root to form an additional apical or lateral foramen.^{3,5}

Dens Invaginatus is often missed during diagnosis and sometimes detected by chance on radiographs. The invagination is vulnerable to caries, which may lead to pulpal complications.⁶ Once the pulp is involved, root canal treatment is required and is a challenge to the dentists. Therefore, early diagnosis is important so that the tooth can be restored before it progresses to infect the pulp.

This article presents a case of Type II DI with pulpal involvement where endodontic management was done.

CASE REPORT

A 23 years old girl reported to the Department of Conservative

Address for correspondence:

¹Post Graduate Trainee (**Corresponding author**)

Mobile: +919003153529

Email: pallavi.yaduka@gmail.com

²Professor

Department of Conservative Dentistry and Endodontics
Regional Dental College, Guwahati.

Mobile: +919864010215

Email: rubikataki@ymail.com

³Post Graduate Trainee

Regional Dental College, Behind GMCH, Bhangagarh,
Guwahati, Assam

Cite this article as: Yaduka Pallavi, Katakhi Rubi, Angami Neingutunuo. Endodontic management of type II dens invaginatus: a case report. *Int J Health Res Medico Leg Prae* 2019 July;5(2):86-89. DOI 10.31741/ijhrmlp.v5.i2.2019.20

Dentistry and Endodontics with the chief complaint of pain in the right upper lateral incisor for the past 1 month. On clinical examination, the right maxillary permanent lateral incisor (12) was tender on percussion. There was discoloration in the developmental groove where the cusp blends with the sloping of the lingual tooth surface. The tooth showed no response to electric and thermal pulp testing. Past Medical history and dental history were insignificant. Intra oral periapical radiograph and Cone Beam Computed Tomography (CBCT) imaging were advised to the patient.

Radiographic report showed a radiopaque structure within the crown of 12, crossing the cemento-enamel junction and extending upto the middle third of the tooth. Widening of periodontal ligament was noticed (**Figure 1**). CBCT showed increased radiodensity similar to enamel within the canal wall in the palatal aspect due to the presence of type II DI which terminated in the middle third of the root canal (**Figure 2**). It revealed two pulpal areas, one central invaginated structure and a larger pulp space surrounding the central structure on all sides within the root canal (**Figure 3**). A single canal, approximately 5.4 mm going beyond the DI was seen.

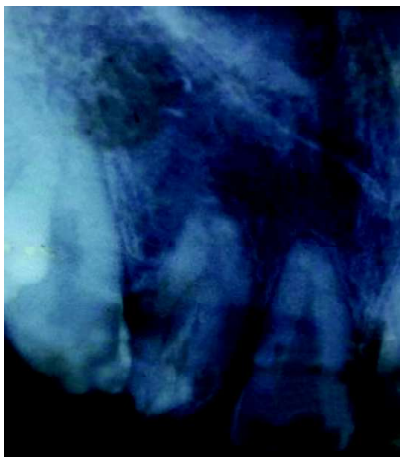

Figure 1 Pre-operative Radiograph

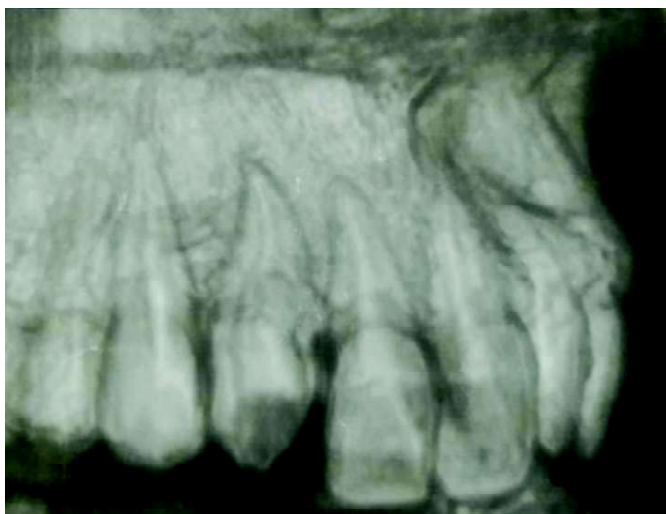

Figure 2 Pre-operative CBCT Image

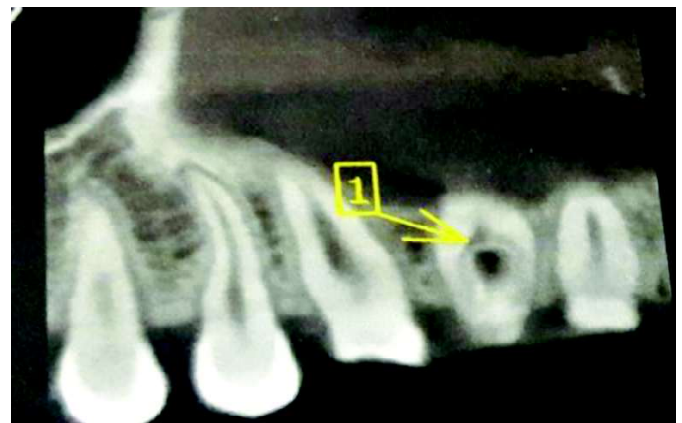

Figure 3 CBCT image showing central anomalous structure surrounded by pulp

A diagnosis of chronic apical periodontitis was made based on the above findings. Root canal treatment followed by post endodontic restoration was planned. The clinical condition was explained and treatment consent was taken from the patient.

Local anaesthesia was administered. Rubber dam isolation and access opening was done. Working length determination was done using Apex locator (Root ZX, J Morita) and confirmed radiographically to be 20mm. (**Figure 4**).

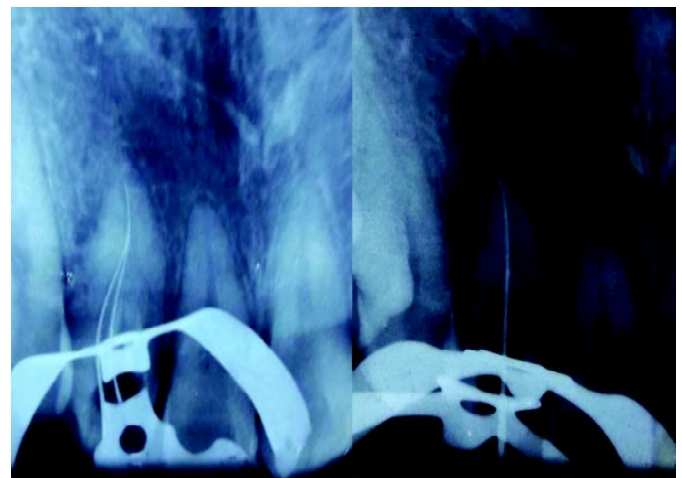


Figure 4 Working length determination radiographs

Complete removal of the central-anomalous structure was done to allow total removal of pulp tissue and create space for debridement and subsequent obturation of the root canal.¹ 25mm K-files were used to prepare the canals. Apical preparation was done till size 55. The canal was prepared by step back technique till size 80. Copious irrigation was done using 3% sodium hypochlorite, saline and 17% EDTA. The prepared canal was dried with absorbent paper points. Canal was obturated by vertical condensation using thermoplasticised gutta percha. Post endodontic restoration was done using composite resin. Tooth remained asymptomatic after a follow up of 3 months and 6 months (**Figure 5 and 6**).

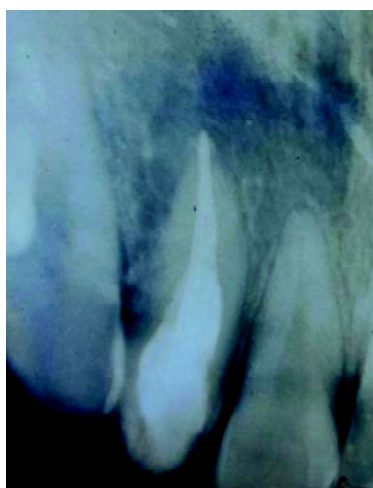

Figure 5 Post-operative radiograph

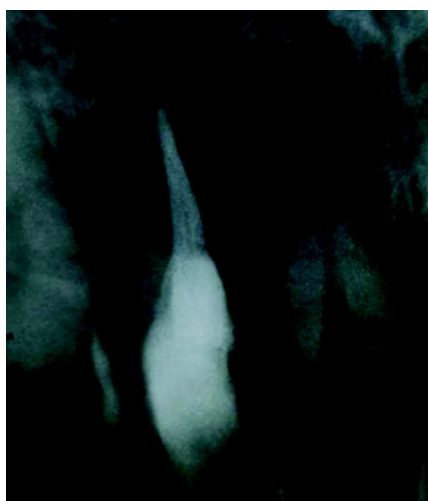

Figure 6 Three months follow-up radiograph

DISCUSSION

Several theories have been proposed to explain the etiology of dens invaginatus but it still remains controversial and unclear.⁶

In 1934, Kronfeld suggested that DI resulted from focal failure of growth of internal enamel epithelium while the surrounding normal epithelium continued to proliferate and engulf the static area.⁷

Rushton, in 1937, proposed that the invagination is a result of aggressive and rapid proliferation of a part of internal enamel epithelium invading the dental papilla.⁸

Atkinson, in 1943, suggested that DI resulted from external forces exerting an effect on the tooth germ during development.⁹

Oehlers (1957) suggested that distortion of the enamel organ during tooth development and subsequent protrusion of a part of the enamel organ leads to the formation of an enamel-lined channel ending at the cingulum or at the incisal tip.^{10,11}

Genetic factors may play a role in formation of DI.¹²

Clinical presentation of DI varies considerably. Clinically, unusual crown morphology like dilated, peg-shaped, barrel-shaped teeth may be seen. The invagination allows entry of irritants into the area, which is separated from pulpal tissue by only a thin layer of enamel and dentine. This leads to development of dental caries which leads to pulpal involvement, sometimes even before root end closure. If untreated, it can lead to abscess formation, cysts, and internal resorption. There is high risk of perforation of the root canal walls when preparing access to the invagination.⁶

CBCT is essential for accurate diagnosis and treatment planning. They provide clear, detailed, 3D images in multiple slices, the number and location of canals, allowing a precise diagnosis of its type, extent, as well as the peri-radicular area.¹³

Complete debridement of the infected canal is the key to the success of endodontic treatment. Thermoplasticised gutta-percha can be useful for sealing anatomically complicated pulp spaces.¹⁴

CONCLUSION

Lack of knowledge of anatomical variations and anomalies associated with each tooth and inadequate skills to manage them can lead to failure of endodontic treatment.

With the limitations of conventional radiographs, it is advisable to use newer diagnostic modalities like CBCT which are useful in the interpretation and treatment planning of complex teeth anomalies.

Conflict of Interest: None.

Contribution of Authors: We declare that this work was done by the authors named in this article and all liabilities pertaining to claims relating to the content of this article will be borne by the authors.

REFERENCES

1. Anup Bhaisare, Ashwini Patil, Manjusha Warhadpande, Sadhana Raina, Asha kalbande. Endodontic Management of Unusual Case of Type II Dens Invaginatus – A Case Report. *Journal of Medical and Dental Science Research* 2017; Vol 4(5);36-42.
2. Pramod SS, Rajitha AV, Menon PR. Dens Invaginatus clinically presenting as a talon cusp – a case report. *IOSR Journal of Dental and Medical Sciences*. Jan 2015;14(1);88-91.
3. Kaan Gunduz, Peruze Çelenk, Emin-Murat Canger, Zeynep Zengin, Pýnar Sümer. A retrospective study of the prevalence and characteristics of dens invaginatus in a sample of the Turkish population. *Med Oral Patol Oral Cir Bucal*. Jan 2013;18(1);e27-32.
4. Gangwar Anshul, Singal Deepa, Giri KY, Agarwal Anshita, Keerthi SS. An Immature Type II Dens Invaginatus in a mandibular lateral incisor with talon's cusp: a clinical dilemma to confront. *Case reports in dentistry*. 2014;826294:1-5.
5. Oehlers FA. Dens invaginatus (dilated composite

- odontome). Variations of the invagination process and associated anterior crown forms. *Oral Surg Oral Med Oral Pathol* 1957;10:1204-18.
6. Thakur Seema, Thakur NS., Bramta Manmohan, Gupta Mohit. Dens invagination: a review of literature and report of two cases. *J Nat Sci Biol Med* 2014 Jan-Jun;5(1):218-21.
 7. Kronfeld R. Dens in dente. *J Dent Res.* 1934;14:49–66.
 8. Rushton MA. A collection of dilated composite odontomes. *Brit Dent J* 1937;63:65-85.
 9. Atkinson SR. The permanent maxillary lateral incisor. *Am J Orthod* 1943;29:685–98.
 10. Oehlers FA. Dens invaginatus I. Variations of the invagination process and associated anterior crown forms. *Oral Surg Oral Med Oral Pathol* 1957;10:1204-18.
 11. Oehlers FA. Dens invaginatus II. Associated posterior crown forms and pathogenesis. *Oral Surg Oral Med Oral Pathol* 1957;10:1302-16.
 12. Hosey MT, Bedi R. Multiple dens invaginatus in two brothers. *Endod Dent Traumatol* 1996;12:44-7.
 13. Mohsen Bahmani, Alireza Adl, Samane Javanmardi, Sina Naghizadeh. Diagnosis and Treatment of a Type III Dens Invagination Using Cone-Beam Computed Tomography. *Iran Endod J* 2016;11(4):341-6.
 14. Ranganathan Jaya, Sundaresan MK, and Ramasamy Srinivasan. Management of Oehler’s Type III Dens Invaginatus Using Cone Beam Computed Tomography. *Case Reports in Dentistry* 2016;3573612.

