

CASE ARTICLE

Squamous Cell Carcinoma Over a Trophic Ulcer in a Patient with Hansen's Disease

Kalita Chayanika¹, Kalita Lohit Kumar², Ali Ahmed³, Sarma Umesh Chandra⁴

Received on March 14, 2015; Accepted (revised) on June 17, 2015

ABSTRACT

Although non healing ulcer in leprosy is a common phenomenon, yet acute malignant transformations of the same are relatively rare. This study reports a 32-year old man previously treated for Hansen's disease with a squamous cell carcinoma involving the left foot with rapid lymphatic spread. He was being treated as a benign trophic ulcer for more than 18 months until he started developing huge inguinal lymph nodes and the ulcer rapidly increased in size. Usually Squamous cell carcinoma are known to occur in ulcers of considerable duration but such rapid growth in such a short duration and rapid lymphatic spread in unusual in as seen in our case as the lymphatics are usually destroyed because of previous inflammation and scarring.

Keywords: *Squamous cell carcinoma, Ulcer, Hansen's disease*

INTRODUCTION

Leprosy or Hansen's disease is a completely curable though difficult to treat mycobacterial disease. The only mycobacterium that can damage nervous tissue, *Mycobacterium leprae* initially damages the peripheral nervous system and then secondarily involves the skin and certain other tissues. Trophic ulcers are very common in the neuropathic feet and these may turn malignant over a long period of time

CASE REPORT

A 32-year-old man, a cultivator by occupation, was referred with a non-healing ulcer involving both feet for more than 9 months. He was not diabetic. He was previously diagnosed with Paucibacillary leprosy and was treated as recommended by the World Health Organization. The patient took rifampicin 600 mg once every 28 days and dapsone 100 mg once daily for 28 days, constituting a cycle. He completed 6 such cycles continuously within a 9-month period. On examination, both lower limb was grossly swollen and edematous with inguinal lymphadenopathy (**Figure 1**). Local examination revealed multiple ulcero-proliferative lesions involving the plantar aspect of both lower limbs up to the region of the lateral malleolus measuring approximately 15 × 10 cm over the left foot and 10cm × 8 cm over the right foot. The ulcer had everted edges and bled easily on touch. There ulcer surrounds were indurated. Examination of the inguinal region revealed bilateral inguinal lymphadenopathy with hard external iliac nodes. An edge wedge biopsy taken from the ulcer was reported as squamous cell carcinoma (SCC). Fine-needle aspiration cytology of the inguinal lymph nodes revealed a spread. A contrast computed

Address for correspondence and reprint:

²Assistant Professor (**Corresponding Author**)

Dept. of Oncology, Gauhati Medical College and Hospital,
Guwahati, Assam

Email: lkkalita2013@gmail.com

Mobile: 9435061804

¹Assistant Professor of Dermatology, Gauhati Medical
College and Hospital, Guwahati

³Assistant Professor of Pathology, Gauhati Medical
College and Hospital, Guwahati, Assam

⁴Vice-Chancellor, Srimanta Sankadeva University of
Health sciences, Guwahati, Assam

tomography scan of the pelvis and abdomen showed para aortic and external inguinal node involvement compressing the right external iliac veins with luminal thrombus. The acute presentation led to the patient being treated on the lines of chronic trophic ulcers. In this patient, the possibility of immunocompromise leading to the rapid malignant transformation cannot be overlooked.

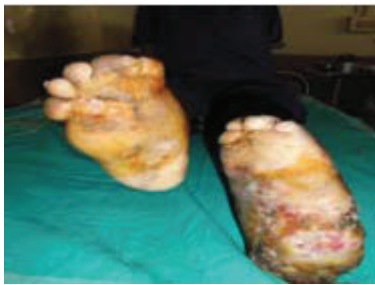

Figure 1 Large areas of planter erosions and ulceroproliferative lesions over both feet (more on left than right) with foot deformity with shorten digits. Ulcer on the left posterior part of sole irregular, ill-defined with hyperkeratotic crusted margins and floor showing dirty slough and unhealthy granulation tissue

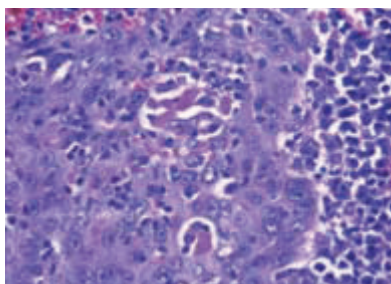


Figure 2 Histopathological examination of the lesion shows a mass of fibrofatty tissue infiltrated by groups of neoplastic cells suggestive of poorly differentiated squamous cell carcinoma (40X)

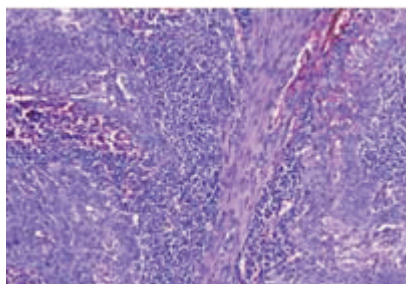


Figure 3 Histopathological examination of the lesion shows a mass of fibrofatty tissue infiltrated by groups of neoplastic cells suggestive of poorly differentiated squamous cell carcinoma (10X)

DISCUSSION

Ulcus Marjolini or Marjolin's ulcer was first described by Jean Nicholas Marjolin in 1828. It is the malignant transformation of any chronic wound, not restricted to burns and presents as an aggressive, ulcerating, squamous cell carcinoma (SCC) in areas of trauma, chronic inflammation, or scarring.¹ They exhibit slow growth and are painless, as the ulcer is usually not associated with nerve tissue, and lack lymphatic spread because of local destruction of lymphatic channels. Lymphadenopathy can be the initial manifestation of leprosy delaying the diagnosis of SCC from lymph node biopsy.² The time taken for malignant transformation in Marjolin's ulcers averages 32.5 years¹ but ranges between 25 and 40 years.³ One case-control study concluded that ulcer duration was significantly lower in the group with malignant change. No correlations were reported between the duration of leprosy, the type and duration of leprosy chemotherapy, presence of bone involvement, and type of ulcer care treatment given.⁴ A study conducted in northern Thailand concluded that most patients were in the Paucibacillary spectrum with trophic ulcers of 12 years duration, whereas our patient presented with malignant transformation in an acute ulcer of 12 months duration. The commonest site of involvement of squamous cell carcinoma was the proximal part of the plantar surface.⁵ Malignant transformation was more common in plantar ulcers of long duration.⁶ A retrospective analysis of chronic ulcers among leprosy patients in Salem, India showed more neoplastic transformation in patients in their sixth decade, the authors' patient was younger, only 32 years. Paucibacillary leprosy patients with nonhealing ulcers of the heel were reported to show a greater predilection for malignancy.⁷ Trophic ulcers of leprosy usually present with infected growths and regional lymphadenopathy and undergo malignant transformation. Lymph nodes regress after removal of the primary and in some cases lymph nodes can be positive for malignancy.⁸ In our patient, the clawing of the feet and the lymph nodes were attributed to the disease. The sudden erosive change in the appearance of the lesion and increase in size prompted further investigation and a diagnosis of squamous cell carcinoma was confirmed. Marjolin's ulcer is usually contained well by wide excision with a margin of at least 1 cm of healthy tissue. However, amputation is the treatment of choice when excision is complicated by bone involvement and infection.⁹ Another method of ensuring complete local excision is the Mohs micrographic surgery.¹⁰ Marjolin's ulcer is aggressive and carries a

high incidence of metastases. Smith et al,¹¹ after studying 21 patients, concluded that malignancy was more common in developing countries where active medical intervention is sought only after complications set in. Our patient sought treatment as the ulcer had been persistent for 12 months, bled on touch and this interfered with his occupation as a tailor. The patient was satisfied with the treatment decision, since he desired relief from the long-standing chronic wound. Very aggressive in nature, Marjolin's ulcers are thought to be caused by long-term, continuous mitotic activity as the epidermal cells attempt to resurface the open defect.¹² The presence of tumor cells prevent the healing of ulcers. It has been suggested that cellular mutations are responsible for neoplastic changes, and infection might serve as a co-carcinogen in scar tissue. It has also been suggested that patients with inherent immune deficiency are at higher risk for developing malignant ulcers.¹³ We report this case for its atypical acute presentation, with lymph node metastasis, in a young patient, which led to overlooking of the diagnosis. The only clues here were the proximal location of the plantar ulcer and the Paucibacillary spectrum.

CONCLUSION

In developing countries, walking bare foot is not uncommon. Trophic ulcers are regularly seen in the clinic, and a high degree of clinical suspicion can go a long way in saving the limbs.

REFERENCES

1. Sabin SR, Goldstein G, Rosenthal HG, Haynes KK. Aggressive squamous cell carcinoma originating as a Marjolin's ulcer. *Dermatol Surg* 2004;30:229-230.
2. Satti MB, al-Mohaya S. Hansen's disease: a cause of lymphadenopathy in endemic areas. *Trop Geogr Med* 1989;41:80-84.
3. Hill BB, Sloan DA. Marjolin's ulcer of the foot caused by nonburn trauma. *South Med J* 1996;89:707-710.
4. Richardus JH, Smith TC. Squamous cell carcinoma in plantar ulcers in leprosy. A case control study. *Lepr Rev* 1993;64:270-274.
5. Richardus JH, Smith TC. Squamous cell carcinoma in chronic ulcers in leprosy: a review of 38 consecutive cases. *Lepr Rev* 1991;62:381-388.
6. Bobhate SK, Madankar ST. Malignant transformation of plantar ulcers in leprosy. *Indian J Lepr* 1993;65:297-303.
7. Kumaravel S. Neoplastic transformation of chronic ulcers in leprosy patients: a retrospective study of 23 consecutive cases. *Indian J Lepr* 1998;70:179-187.
8. Dupree MT, Boyer JD. Marjolin's ulcer arising in a burn scar. *Cutis* 1998;62:49-51.
9. Christopher JW, Li BD, Gonzalez E, Valiulis JP, Cunningham M, McCulloch J. Nonhealing ulcer in a diabetic foot. *Wounds* 2004;16:212-217.
10. Rahimizadeh A, Shelton R. The development of a Marjolin's cancer in a human immunodeficiency virus-positive hemophilic man and review of the literature. *Dermatol Surg* 1997;23: 560-563.
11. Smith J, Mello LF, Nogueira Neto NC, et al. Malignancy in chronic ulcers and scars of the leg (Marjolin's ulcer): a study of 21 patients. *Skeletal Radiol* 2001;30:331-337.
12. Lawrence WT. Clinical management of nonhealing wounds. In: Cohen IK, Diegelmann RF, Lindblad WJ, eds. *Wound Healing*. Philadelphia, PA: W. B. Saunders; 1992:541-546.
13. Thio D, Clarkson JH. Malignant change after 18 months in a lower limb ulcer: acute Marjolin's revisited. *Br J Plast Surg* 2003;56:825-828.