

CASE ARTICLE

## Laboratory Diagnosis of Cutaneous (Dermal) Leishmaniasis with Hansen's Disease

**Sonowal Basanta\***

*Received on June 27, 2015; Accepted (revised) on August 27, 2015*

### ABSTRACT

*Post kala-azar dermal leishmaniasis (PKDL) is a dermatosis that occurs as a sequel of visceral leishmaniasis (VL). Elimination of VL requires detection and treatment of PKDL, necessarily because of its capacity to serve as a reservoir for the causative parasite, Leishmania donovani. Diagnosis of PKDL presents a challenge due to low parasite burden in the lesions with Hansen's disease. We report such a case of Cutaneous Dermal Leishmaniasis with Hansen's disease in Guwahati in a 56 year old male patient who migrated from Bihar to Assam in Guwahati Medical College. Leprosy is a chronic infectious disease caused by M. Leprae bacilli. It affects mostly peripheral nerves and also affects the skin, muscles, the eyes, testes, bones and internal organs. This patient came to the clinical laboratory with typical clinical presentation. In this case I have carried out the routine examination of blood, cytological, AFB, histological, bone marrow examination and aldehyde test for confirmation of diagnosis.*

**Keyword:** Laboratory diagnosis, Dermal Leishmaniasis, Hansen's disease

### INTRODUCTION

Leishmaniases, in its variety of visceral (VL), cutaneous (CL) and mucocutaneous (MCL) forms, directly affects about 2 million people per annum, with approximately 350 million individuals at risk worldwide. During the last 10 years there have been extensive epidemics of visceral form of the disease, which is also emerging as an important opportunistic infection in immunocompromised patients, especially those co-infected with HIV.<sup>1</sup> Leishmaniasis is a group of disease caused by various species of the protozoan parasites of the genus Leishmania. Leishmaniasis can be categorized in 3 major forms ranging in severity from spontaneously healing skin ulcers in cutaneous Leishmaniasis (CL), destructive mucocutaneous leishmaniasis (MCL) to fatal visceral leishmaniasis (VL). The disease remains a major health problem, being currently prevalent in 88 countries, infecting 12 million individuals and threatening 350 million people.<sup>2</sup>

Post kala-azar dermal Leishmaniasis with leprae bacilli infections are endemic in India. PKDL is a rare group of protozoal disease caused by parasite of the genus leishmania, and transmitted to man by the bite of female phlebotomine; sand fly and they are responsible for various syndromes in human beings.<sup>3,4</sup>

Co-infection post kala-azar dermal Leishmaniasis (PKDL) with leprosy is an infrequent complication. PKDL is a protozoal disease known to occur epidemically and endemically in well-defined areas in the eastern sector of the country, Assam, West Bengal, Bihar, Madhya Pradesh, Tamil Nadu and Orissa.<sup>5,6</sup>

During the eradication campaign between 1958-1964, kala-

---

### Address for correspondence and reprint:

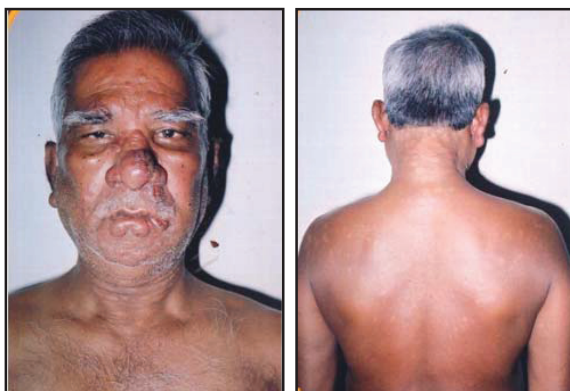Assistant Professor of Pathology  
Tezpur Medical College, Tezpur  
**Email:** basantasonowalghy@gmail.com  
**Mobile:** 09864039387

azar and cutaneous leishmaniasis declined to a point of extremely low endemically, but during this period, some patients with PKDL apparently acted as a reservoir of infection, since periodically new cases of kala-azar have been seen. Leprosy is a chronic infectious disease and it is a major public health problem in India and it has got long incubation period, an average of 3-4 years.<sup>7</sup> Risk factor for both the disease are poverty, malnutrition, deforestation and urbanization. Clinically kala-azar and leprosy is very difficult to differentiate from each other because sign and symptoms are almost same for both. So in this particular case, diagnosis is established by demonstration of L.D body and AFB bacilli.

Here in this case I have reported a case of co-infection by kala-azar with leprosy diagnosed with the help of cytological, hematological, histological, AFB stains and biochemical study.

#### CASE HISTORY

A 56 year old male patient who migrated from Bihar to Assam a few months ago, came to the hospital with a history of treatment with some medication for his problem, which was not cured, instead increased and spread all over the body. He presented with unexplained fever, weight loss, loss of appetite, weakness, itching, redness, and progressive emaciation, hoarseness of voice etc. On examination, the patient had percutaneous nodule all over his body, hypopigmented areas both side upper part of the body, skin dryness and ulceration found at the angle of mouth, cheek and nose. Loss of sensation at the hypopigmented areas and oozing from the ulcerative areas, muscle weaknesses are also observed. Both side of the inguinal lymph node was positive, it was non-tender and fixed, liver and spleen enlarged.



**Figure 1** Nodulo-ulcerative lesion over the face (A), hypopigmented areas on back (B)

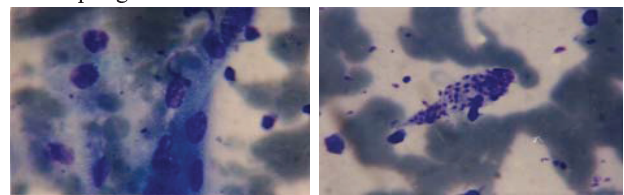
#### DIFFERENT LABORATORY METHODS

Routine Blood examination: TC- 4000, DLC- 46+50+1+3, Hb-9.6gm/dl, ESR- 112 AEFH

Routine urine examination is normal.

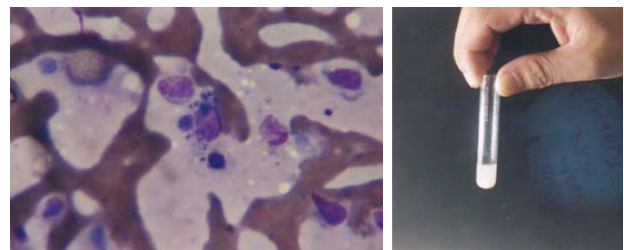
**Biochemical Test** shows increase IGE and SGOT, SGPT.

**HAEMATOLOGICAL TEST:** Leishmanstain's from peripheral blood-smear reveals engulfing body by macrophages.



**Figure 2** PBS shows presence of L.D. Bodies singly and clusters

**Bone marrow aspiration's** smear reveals L.D. body as shown in **Figure 3 (A)**.

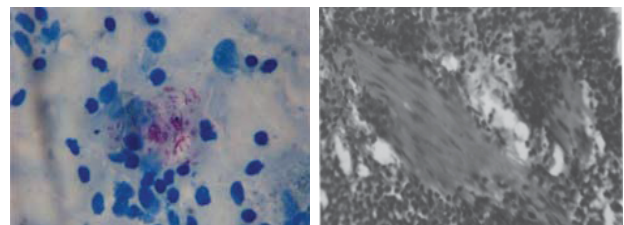


**Figure 4 (A)** Bone marrow findings of LD Body (Giemsa Stain), **(B)** Aldehyde Test (+++)

**Cytological Examination:** Giemsa stains-smear taken from the ulcerative sites- smear reveals L.D. body lying singly and clusters.

**Formal Gel Test:** Aldehyde test was strongly positive (+++) as shown in **Figure 5 (B)**.

**Slit's smear for AFB:** Zeihl nelson stains smear reveals clusters and Globi of AFB bacilli and also the histological section shows thicken nerve fibers with inflammatory changes as shown in **Figure 4**.



**Figure 6 (A)** Zeihl Nelson stains reveals clusters and Globi of AFB bacilli, **(B)** H and E section shows thicken nerve fibers with inflammatory changes

## DISCUSSION

Here, the diagnosis of Cutaneous Dermal Leishmaniasis with Hansen's disease is based on clinical and epidemiological parameters. Demonstration of parasite in the slit smear or by culture of the dermal tissue is considered to be the gold standard, but the methods involved are invasive, less sensitive (58%) and difficult to perform in field conditions.<sup>8</sup> As the patient was diagnosed with co-infection by Kala-azar and leprosy all the possible laboratory tests has been done. The patient clinical finding for Kala-azar and leprosy goes for the favours of the disease and this is confirmed by clinical and positive laboratory findings. As the clinical findings of the patient have darkening of face, hands, feet, abdomen is the common site of the patient in tropical areas. Sometimes diffuse cutaneous Leishmaniasis<sup>9</sup> may confuse with leprosy because the agent is restricted to the skin. This patient has ulcer at the angle of mouth, nose, hypopigmented area both side of the back redness some areas of the body. To measure of nerve conduction test was positive and it is a favor for the clinical diagnosis of the leprosy concomitantly with kala-azar. **Table 1** shows the diagnostic evidence of kala azar and leprosy.

**Table 1** Diagnostic evidence of kala azar and leprosy

Direct Evidence	Indirect Evidence
Peripheral blood smears examination.	Haemogram reveals anemia and leucopenia.
Blood culture	Serological test
Biopsy	Aldehyde test
Bone marrow examination	CFT, Immunological assay
Blood culture also done for L.D body in a case of kala azar	

Methods for the diagnosis of VL often lack sensitivity or specificity for the diagnosis as (i) the number of parasites in skin smears and biopsy specimens is often low, thus requiring prolonged searches by routine microscopy.<sup>8, 10, 11</sup>

In this particular case with typical clinical presentation and the most significant laboratory finding was demonstration of Donovan bodies in peripheral blood smear by Giemsa and leishman's stains. Identification of L.D bodies in bone marrow and cytological smear appears as ovoid or rounded body measuring 1-3 mm in length and lying intercellularly in monocytes, polymorphs or endothelial cells.

For better control management of Kala-azar, control the reservoir and treat with sodium stibogluconate. To measure of leprosy medical measures like multi-drug therapy, health education, immunoprophylaxis, rehabilitation and social support are some of the important measurement.

## CONCLUSION

Kala-azar is not completely eradicated in the tropical countries like India and some cases are found periodically in north eastern part of India and all the age group irrespective of sex are the sufferer.

Leprosy and kala-azar are the major public health problem in India and it has a similar immunological spectrum that occurs concomitantly in the endemic region.

VL transmission in India is thought to be anthroponotic and in the absence of animal reservoirs, PKDL patients are deemed singular source of the parasite *L. donovani*. Therefore, rapid, sensitive and specific tools for identifying *dermal leishmaniasis* are required because they are highly desirable that would allow control interventions in endemic area of VL, a prerequisite for successful elimination of VL.

**Conflict of interest:** None declared.

**Consent of the case:** Inform consent taken.

## REFERENCE

- Shradha A. Sane. Antileishmanial treatment using chemotherapy in combination with immunomodulators in experimental Visceral Leishmaniasis. Thesis 2010 [cited 2015 July 24];[7]. Available from: URL:<http://dkr.cdri.res.in:8080/dspace/bitstream/123456789/1260/1/S-250-Shradha+A.+Sane-2010.pdf>
- Poonam Salotra and Ruchi Singh. Challenges in the diagnosis of post kala-azar dermal leishmaniasis. *Indian J Med Res* 123 March 2006; pp 295-310.
- ABCD Sundar, S; Chakravarty, J. Leishmaniasis: on update of current pharmacotherapy. *Expert opinion on pharmacotherapy* 2013 Jan;14(1):53-63.
- Ejazi: SA, Ali, N. Expert review of anti infective therapy 2013 Jan;11(1):79-98.
- Indian J. Dermatol. Veneral Leprol* 2013 May-June;79(3):360-6.
- Leishmaniasis fact Sheet N "N 375" World Health Organization January 2014. Retrieved 17 Feb 2014.
- Dipendra K. Mitra, Veena Taneja, Raja Rajalingam, Narinder K. Mehra, Tapas K. Marti, Abhijit Banerjee, Bimal C.

- Bhattacharya, et al. CD4+ T-cell responses to recombinant hsp65 and hsp18 of *M. leprae* and their Trypsin-digested fragments in leprosy: diversity in HLA-DR restriction 1995;63(4):518–28.
8. Singh RP. Observation on dermal leishmanoid in Bihar. *Indian J Dermatol* 1968;13:59-63.
9. Cox FE. History of human parasitology. *Clin microbial Rev* 2002;15(4):595-612.
10. El Hassan AM, Ghalib HW, Zijlstra EE, Eltoum IA, Satti M, Ali MS, et al. Post kala-azar dermal leishmaniasis in the Sudan: clinical features, pathology and treatment. *Trans R Soc Trop Med Hyg* 1992;86:245-8.
11. Ghosh MK, Nandy A, Addy M, Maitra TK, Ghose AC. Subpopulations of T lymphocytes in peripheral blood, dermal lesions and lymph nodes of post kala-azar dermal leishmaniasis patients. *Scand J Immunol* 1995;41:11-7.

## For best acceptance of your article

### SELF-TECHNICAL REVIEW OF ARTICLE

#### BASIC INSTRUCTIONS

In conducting your technical review, please consider the guidelines shown on page two of this form. You may complete this form & put your comments in the database as follows:

**Type of article:** / / Review Paper / / Original Paper / / Case Report / / Critical Review / / Book Review / / Other

**Author(s):**

**Title:**

**Reviewer's name and address** (Please indicate here if you agree to allow your name to be released to the list of reviewer board):

Tel:

Fax:

E-mail:

#### RECOMMENDATIONS

**Acceptability for publication (Mark X):**

- Accept, as is or with minor editorial changes or clarifications
- Provisionally Accept
- Minor technical issues need attention
- Minor problems exist in presentation (organization, length, logic, conclusions, etc)
- Provisionally not accept
- Significant technical issues need resolution
- Major problems exist in presentation (organization, length, logic, conclusions, etc)
- Not accept
- Subject matter is not suitable for IJHRMLP
- Technical content of article is not sound
- Technical content of article lacks sufficient substance

**Specific comments** (please use additional sheet as appropriate):

**Signature**

**Date:**