



RESEARCH PAPER

Clinical and hemodynamic assessment of patient receiving prosthetic mitral valve replacement

Talukdar Mrinmoy¹,
Konwar Ranjumoni²,
Deka Arun³

¹Assistant Professor
Department of Cardiothoracic and
Vascular Surgery
Gauhati Medical College and Hospital,
Guwahati, Assam, India
Email: drmrinmoytalukdar@gmail.com
Mobile: +919854027404

²Associate Professor
Department of Radiology
Fakhruddin Ali Ahmed Medical
College and Hospital, Barpeta, Assam
Email: rknjournalcorrespond@gmail.com

³Department of Pain and Palliative
Care (**Corresponding Author**)
State Cancer Institute
Gauhati Medical College and Hospital
Guwahati, Assam, India
Email: drarundeka25@gmail.com
Mobile: +919864096265

Received on: Dec 30, 2019
Editorial approval on: Jan 25, 2020
Plagiarism checked: Yes
Peer review: Double blinded
Peer review comments: Four
Editor who approved:
Prof. Putul Mahanta

Background and aims: Mitral valve replacement by mechanical or bioprosthetic valves revolutionized the care of patients with severe mitral valve disease. Mitral valve is commonly affected by Rheumatic heart disease, leading to the development of mitral stenosis and regurgitation requiring prosthetic replacement. The clinical and hemodynamic assessment of patients undergoing mitral valve replacement is substantial in measuring the extent of morbidity. The present study assesses patients' pre and post-operative hemodynamic parameters having mitral valvular diseases requiring prosthetic replacement. **Materials and methods:** The study included 45 selected cases of the mitral valvular lesion that underwent prosthetic replacement of mitral valve admitted in the cardiothoracic surgery department at a tertiary care centre. A detailed history of each patient was taken, and subsequent management and follow up was done. The hemodynamic assessments of the patients were performed by invasive pressure measurement and by echocardiographic measurement during preoperative, post-operative and follow-up period. Statistical analysis was performed with the Quick Calcs Online calculator (Graph Pad Software). Continuous variables are expressed as mean and standard deviation after checking for normality of distribution. Differences between baseline and follow-up were analyzed using paired t-test. A p-value of <0.05 was considered statistically significant. **Results:** A total of 45 patients of age ranging from 14 years to 65 years undergoing mitral valve replacement were included in the study. Substantial decrease in the mean pulmonary artery (PA) and left atrium (LA) pressure were observed after valve replacement compared to pre valve replacement in all the three valvular lesion groups, i.e., mitral stenosis, mitral regurgitation and combined valvular lesion groups with p-value <0.0001. The subsequent decrease in left atrial diameter post-operative six months was also noted in all the groups. No significant postoperative improvement in ejection fraction was noticed in the mitral stenosis and mitral regurgitation group. Considerable progress in mean transmitral gradient after valve replacement is seen among all the groups (p-value <0.0001) with a substantial decrease at six-month post-operative compared to the preoperative trans-mitral gradient. **Conclusion:** Steady, significant improvement in patients with different valvular abnormalities is noticed after prosthetic replacement of the mitral valve. Prosthetic replacement of mitral valve provides satisfying hemodynamic improvement.

Keyword: Rheumatic heart disease; mitral valve; mitral stenosis; mitral regurgitation; hemodynamics; echo-cardiography.

Cite this article: Talukdar Mrinmoy, Konwar Ranjumoni, Deka Arun. Clinical and hemodynamic assessment of patient receiving prosthetic mitral valve replacement. *Int J Health Res Medico Leg Prae* 2021 Jan-Jun;7(1):77-83. Doi: 10.31741/ijhrmlp.v7.i1.2021.13.

INTRODUCTION

The prevalence of rheumatic heart disease varies widely by region. It is more prevalent in developing countries with 5.5-5.7 per 1,000.¹ Rheumatic fever is the leading cause of mitral valve disease globally, particularly in developing countries. However, a global decline in its prevalence is noticed over the years.² The mitral valve is a dual-flap valve in the heart between the left atrium (LA) and the left ventricle (LV). The mitral valve is commonly affected by Rheumatic Heart Disease (RHD), leading to mitral stenosis and regurgitation development.³ The predominant cause of Mitral Stenosis (MS) characterized by narrowing the mitral valve orifice is rheumatic fever.⁴ The mitral valve apparatus involves the mitral leaflets, chordae tendineae, papillary muscles and a mitral annulus; abnormalities of any of these structures may cause Mitral Regurgitation. MR is caused by the retrograde flow of blood from the Left Ventricle (LV) into the Left Atrium (LA) through the mitral valve.⁵

To improve the patient's survival and enhance his quality of life with severely diseased valves, implantation of a functional valve is necessary.^{6,7} A perfect prosthetic replacement for every patient is not available until the late 1950s and early 1960s with the development of reliable, quality-controlled prosthetic heart valve devices that could effectively replace a diseased, non-reparable mitral valve with relative ease of implantation and assurance that the hemodynamic abnormalities from either mitral stenosis or mitral regurgitation were corrected and maintained indefinitely.⁸

Mitral valve disease with regurgitation and stenosis gives rise to various hemodynamic consequences. Longstanding left ventricular volume overload may compromise left ventricular function.⁹⁻¹¹ If the mitral valve disease is of rheumatic origin, left ventricular function may also be depressed due to myocardial fibrosis, secondary to myocarditis.¹² Pulmonary venous congestion may result in pulmonary hypertension; with time, pulmonary vascular disease may develop, compromising the return to normal pressures after mitral valve function is restored. Severe mitral valve disease often requires valve replacement, which is usually reserved for very disabled patients. Various degrees of left ventricular dysfunction and pulmonary hypertension is usually present, and the reversibility of such changes is uncertain. Hemodynamic assessment after mitral valve replacement is of use and has often been performed in adult patients.¹³⁻¹⁷

Therefore, the present study aims for the hemodynamic assessments of patients having mitral valvular diseases requiring prosthetic replacement during preoperative and postoperative periods. Echocardiography evaluation of cardiac chamber size, pressure gradient and ejection fraction was done in different valvular lesion groups and the hemodynamic assessment of patients in the perioperative period before and after valve replacement by the invasive method.

MATERIAL AND METHODS

The study included 45 selected cases of the mitral valvular lesion that underwent prosthetic replacement of mitral valve admitted in the cardiothoracic surgery department at a tertiary care centre. A detailed history of each patient was taken, and subsequent management and follow up was done. Prosthetic replacement of mitral valve was done under total cardiopulmonary bypass with bicaval cannulation. In all cases, the mechanical prosthetic valve was used. The hemodynamic assessments of patients were done during the perioperative period by invasive pressure measurement and echocardiographic measurement during preoperative, postoperative, and follow-up periods. The values obtained were presented separately for the groups of patients with different valvular malformation.

As a part of the Hemodynamic study, direct Invasive Pressure Measurement (IPM) was taken in the Pulmonary Artery (PA) and Left Atrium (LA) before and after valve replacement along with systemic pressure in that time. In all cases, pressure measurement was done using one pressure monitoring line, one 26-gauge needle, and an invasive pressure monitor (BPL multiparameter monitor, Ultima model).

Echocardiographic examination was performed according to the ASE guidelines¹⁸ using an ultrasound system (ACUSON CV 70, Siemens Healthcare, Erlangen, Germany and Hitachi EUB-5500 ultrasound scanner with TEE facility, Japan) equipped with a wideband transducer with multihertz imaging and tissue harmonic imaging capability. Standard echocardiography included parasternal long axis, parasternal short axis, apical four-chamber and subcostal views. The parameters measured explicitly during preoperative, post-operative and in the subsequent follow-up period were:

a) Left atrial diameter measured using M-mode scan of parasternal long-axis view (PLAX) and parasternal short-axis view (PSAX)

b) The percentage change in LV volume between systole and diastole called ejection fraction, which is calculated by the formula $EF = \frac{LVEDV-LVESV}{LVEDV} \times 100\%$

The usual range of EF is 50-75%. The LV internal dimension in end-systole (LVESD) and end-diastole (LVEDD) are measured on the M-mode tracing in the parasternal long-axis view (PLAX), at the level of mitral valve leaflet tips. In Simpson's method, calculation of EF is done by using 2D echo in apical 4 chamber view to estimate LV volume in end-diastole (LVEDV) and end-systole (LVESV). This is done by tracing the LV endocardial borders of a systolic and a diastolic LV frame while the online computer software of the echo machine calculates the LV volumes. From this volume, the ejection fraction can be calculated, and

c) Mean left atrial-left ventricular gradient. The mean pressure gradient across the mitral valve is calculated using Doppler

echo in the apical 4 chamber view. When the pressure gradient is more than 10 mm of Hg, it is considered severe mitral stenosis.

After prosthetic replacement of the mitral valve, as a part of the hemodynamic assessment, all patients were followed up with echocardiography at the 1st month, 3rd months and 6th months in the postoperative period. Regular measurements of LA diameter, ejection fraction, and trans-mitral gradient were done in the follow-up period and compared with the preoperative readings in three valvular lesions.

Statistical analysis was performed with the Quick Calcs Online calculator (GraphPad Software). Continuous variables are expressed as mean and standard deviation after checking distribution normality. The paired t-test used to test significant differences between baseline and follow-up values of variables. A p-value < 0.05 was considered statistically significant. Ethical clearance was taken before the collection of the data from the institutional ethics committee.

RESULTS

During the study period, 45 cases were selected for prosthetic replacement of the mitral valve out of 284 patients with mitral valvular diseases admitted to the Cardio-thoracic Department. The age of the patients ranged from 14-65 years. The majority of the patients (62.2%) were females. The valvular malformations were observed predominantly as mitral regurgitation (37.8%), combined valvular lesion (37.8%) and mitral stenosis (24.4%).

Hemodynamic assessment using IPM in the different valvular lesion group: Among the 11 patients with mitral stenosis, the mean PA and LA pressure was observed to be significantly reduced after valve replacement. A similar reduction in mean PA and LA pressure was also observed among those with mitral regurgitation and combined valvular lesion with a p value <0.0001 in all the above conditions (**Table 1**).

Table 1 Invasive Pressure Measurements among different valvular lesion groups

Valvular Lesion group	IPM	Before Valve replacement		After Valve replacement		p-value
		Mean	S.D.	Mean	S.D.	
Mitral Stenosis (n=11)	PA	54.18	18.26	44.36	15.57	<0.0001
	LA	31.64	5.52	19.73	2.9	<0.0001
Mitral regurgitation (n=17)	PA	33.82	11.02	28.88	10.14	<0.0001
	LA	24.35	8.5	18.24	5.77	0.0003
Combined valvular lesion (n=17)	PA	37.71	12.71	31.35	13.13	<0.0001
	LA	23.76	6.21	17.35	4.03	<0.0001

Comparison of pre and post-operative left atrial diameter among different valvular lesion groups: The comparison of left atrial diameter before and after valve replacement with subsequent follow-up period in predominant Mitral stenosis is shown in **Figure 1**. The mean and SD of left atrial diameter

in preoperative and post-operative after six months were found to be 51.82±7.61 and 32.45±5.94, respectively. The difference was highly significant, with a p value less than 0.0001.

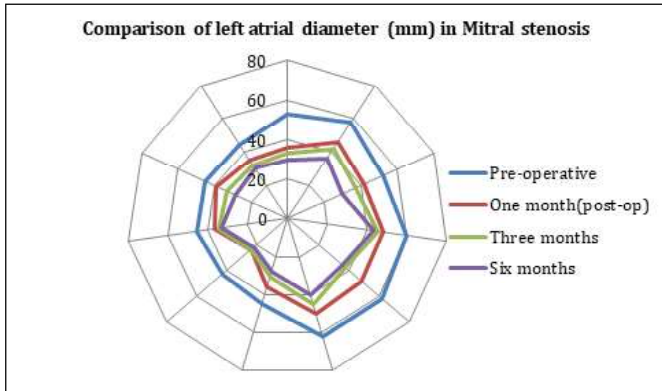


Figure 1 Left atrial diameter in the preoperative and postoperative period in Mitral stenosis.

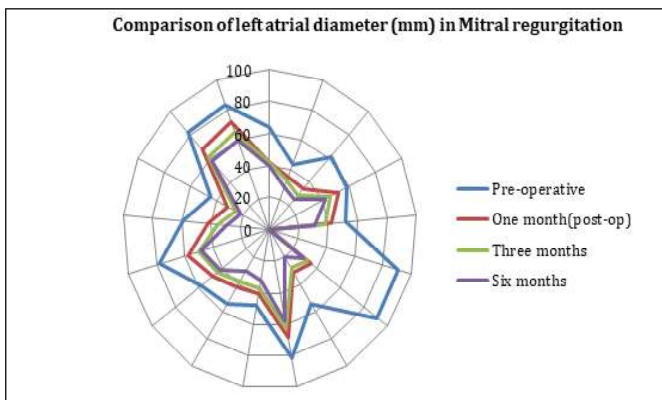


Figure 2 LA diameter in the preoperative and postoperative period in mitral regurgitation

In the predominant Mitral regurgitation group, the mean(\pm SD) left atrial diameter in the preoperative period was 65.12(\pm 16.07) substantially reduced to 37.19(\pm 13.04) post-operative after six months with p-value<0.001 (**Figure 2**).

Among patients with the combined valvular lesion, the comparison of left atrial diameter before and after valve replacement with subsequent follow-up period showed a significant decrease (p-value<0.0001) in mean (\pm SD) left atrial diameter from 61(\pm 9.35) in the preoperative period to 37(\pm 9.8) in the post-operative period after six months as shown in **Figure 3**.

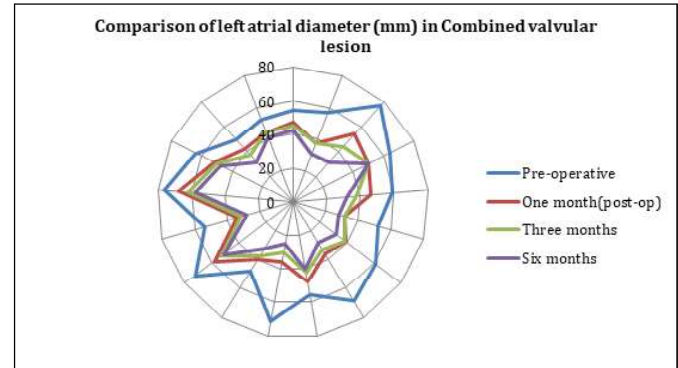


Figure 3 LA diameter in the preoperative and postoperative period in combined valvular lesion

Comparison of Ejection fraction in different valvular lesion group: The comparison of ejection fraction before and after valve replacement with subsequent follow-up period among different valvular lesion groups were presented in **Table 2**.

Table 2 Ejection fraction among different valvular lesion groups

	Mitral Stenosis			Mitral regurgitation			Combined valvular lesion		
	Mean	S.D.		Mean	S.D.		Mean	S.D.	
Pre-operative	57.36	7.62		60.38	6.36	-	60.76	6.57	
1month post op	51.73	5.62	0.057	53.06	8.03	<0.01	56.24	7.79	0.019
3months post op	57.00	5.49	0.89	55.19	6.41	<0.01	59.88	7.74	0.64
6month post op	61.09	4.95	0.064	61.38	6.47	0.41	66.35	6.29	0.001

The mean ejection fraction in preoperative and postoperative periods was not statistically significant in the predominant mitral stenosis group. While in the case of MR, a substantial decline in mean ejection fraction was observed during the first month of post-operative compared to the preoperative mean ejection fraction. However, the mean ejection fraction gradually increased over time with a mean ejection fraction of 61.38 at 6 months follow up with no significant difference

with the mean preoperative ejection fraction of 60.38. In patients with combined valvular lesions, a significant decrease in mean ejection fraction were observed at the month of follow up after valve replacement which eventually increased in subsequent follow-ups.

Comparison of pre and post-operative mean trans-mitral gradient among different valvular lesion groups:

Table 3 Mean trans-mitral gradient among different valvular lesion groups

	Mitral Stenosis			Mitral regurgitation			Combined valvular lesion		
	Mean	S.D.		Mean	S.D.		Mean	S.D.	
Pre-operative	11.27	3.04		10.75	4.88		13.29	4.65	
1month post-op	2.97	0.54	<0.001	3.20	0.62	<0.001	3.31	0.75	<0.001
3months post-op	2.64	0.48	<0.001	2.76	0.49	<0.001	2.86	0.73	<0.001
6months post-op	2.13	0.48	<0.001	2.28	0.41	<0.001	2.41	0.64	<0.001

The comparison of mean trans-mitral gradient before and after valve replacement with subsequent follow-up period in predominant Mitral stenosis group showed a significant decrease in postoperative period over time from the preoperative mean trans-mitral gradient with p-value <0.001. Similar kinds of a substantial reduction in trans-mitral gradient over time were also observed among the Mitral regurgitation group (p-value <0.001). The highest mean trans-mitral gradient at the preoperative period was observed among the combined valvular lesion group with a mean (\pm S.D.) of 13.29(\pm 4.65) which significantly decreased to 2.41(\pm 0.64) in six months postoperative period (**Table 3**).

DISCUSSION

In the present study, hemodynamic assessments were done using echocardiography in all cases in the preoperative, postoperative period and in follow-up period to measure the left atrial diameter, ejection fraction and mean transmitral gradient and data were analyzed separately for different valvular lesion groups. Also, direct invasive pressure measurement was taken in PA and LA before and after valve replacement for perioperative hemodynamic assessment.

In the present study, the substantial reduction in both mean PA and mean LA pressure after valve replacement comparing to pre valve replacement were noted in all the three valvular lesion groups with a p-value <0.0001. A similar type of hemodynamic improvement was noted in various other studies.^{16,17,19-23}

Ejection fraction is significantly improved in the combined valvular lesion group but not in mitral stenosis or mitral regurgitation group in six-month post-operative follow up in the present study. A non-significant ejection fraction in the post-operative period probably due to myocardial injury caused by a chronic volume overload, and the sequelae of rheumatic carditis is reported in another study.²⁴ In patients with mitral stenosis, moderately reduced left ventricular (LV) ejection fraction (EF) may be due to either depressed myocardial contractility or alterations in loading conditions.²⁵

The echocardiography measurements in the present study reveal a significant reduction in mean left arterial diameter and trans-mitral gradient post-operatively in the three groups. Significant decreases in mean trans-valvular pressure gradient (MPG) over time following MVR were reported in another

study with no substantial variation among patients with or without prosthesis-patient mismatch.²⁶

Limitation: The total number of patients evaluated in this study was small, and the present result represents only the early assessments within the first six months after surgery. Cath study was not done in the preoperative and postoperative period to assess the hemodynamic status, which was the major limitation of this study. In this study, changes of hemodynamics in between rest and exercise could not be measured. Also, left ventricular end-diastolic pressure was not measured due to the limitation of the cath study.

CONCLUSION

Hemodynamic assessment was made during pre, peri and post-operative period, which shows steady improvement in patients with predominantly stenotic, predominantly regurgitant and combined valvular lesion groups after prosthetic replacement of mitral valve procedure. The results of this study are comparable to other similar published clinical observations. Prosthetic replacement of mitral valve provides gratifying hemodynamic improvement.

REFERENCES

- Carapetis JR, Steer AC, Mulholland EK, Weber M. The global burden of group A streptococcal diseases. *Lancet Infect Dis* 2005;5(11):685-94.
- Iung B, Baron G, Butchart EG, Delahaye F, Gohlke-Bärwolf C, Levang OW, et al. A prospective survey of patients with valvular heart disease in Europe: The Euro Heart Survey on Valvular Heart Disease. *Eur Heart J* 2003;24(13):1231-43.
- Dass C, Kanmanthareddy A. Rheumatic heart disease. In: *StatPearls*. Treasure Island (FL): StatPearls Publishing; 2020.
- Shah SN, Sharma S. Mitral Stenosis. In: *StatPearls*. Treasure Island (FL): StatPearls Publishing; 2021.
- Douedi S, Douedi H. Mitral Regurgitation. In: *StatPearls*. Treasure Island (FL): StatPearls Publishing; 2021.
- Rahimtoola SH. Choice of prosthetic heart valve in adults an update. *J Am Coll Cardiol* 2010;55(22):2413-6.
- Arora S, Misenheimer JA, Ramaraj R. Transcatheter aortic valve replacement: Comprehensive review and present status. *Tex Heart Inst J* 2017;44(1):29-38.
- Harken DE, Taylor WJ, Lefemine AA, Lunzer S, Low HB, Cohen ML, et al. Aortic valve replacement with a caged ball valve. *Am J Cardiol* 1962;9:292-9. Doi: 10.1016/0002-9149(62)90047-4
- Jaakani JMM, Graham TP Jr, Canent RV Jr, CappMP. The effect of corrective surgery on left heart volume and mass in children with the ventricular septal defect. *Am J Cardiol* 1971;27:254-8.
- Peterson CR, Herr R, Crisera RV, Starr A, Bristow JD, Griswold HE. The failure of hemodynamic improvement after valve replacement surgery. *Ann Intern Med* 1967;66:1-24.
- Ramakrishna H, Craner RC, Devaleria PA, Cook DJ, Housmans PR, Rehfeldt KH. Valvular Heart Disease. In: *Kaplan's Essentials of Cardiac Anesthesia*. Elsevier; 2018. p. 352-84.
- Maganti K, Rigolin VH, Sarano ME, Bonow RO. Valvular heart disease: diagnosis and management. *Mayo Clin Proc* 2010;85(5):483-500.
- Braunwald E, Braunwald NS, Ross J Jr, Morrow AG. Effects of mitral valve replacement on the pulmonary vascular dynamics of patients with pulmonary hypertension. *N Engl J Med* 1965;273:509-14.
- Zener JC, Hancock EW, Shumway NE, Harrison DC. Regression of extreme pulmonary hypertension after mitral valve surgery. *Am J Cardiol* 1972; 30: 820-6.
- Bristow JD, Kremkau EL. Hemodynamic changes after valve replacement with Starr-Edwards prostheses. *Am J Cardiol* 1975;35:716-24.
- Bayat F, Aghdaii N, Farivar F, Bayat A, Valeshabad AK. Early hemodynamic changes after mitral valve replacement in patients with severe and mild pulmonary artery hypertension. *Ann Thorac Cardiovasc Surg* 2013;19(3):201–6.
- Tempe DK, Hasija S, Datt V, Tomar AS, Virmani S, Banerjee A, et al. Evaluation and comparison of early hemodynamic changes after elective mitral valve replacement in patients with severe and mild pulmonary arterial hypertension. *J Cardiothorac Vasc Anesth* 2009;23(3):298-305.
- Douglas PS, Khandheria B, Stainback RF, Weissman NJ, Brindis RG, Patel MR, et al. ACCF/AHA/ACEP/ASNC/SCAI/SCCT/SCMR 2007 appropriateness criteria for transthoracic and transesophageal echocardiography: A report of the American college of cardiology foundation quality strategic directions committee appropriateness criteria working group, American society of echocardiography, American college of emergency physicians, American society of nuclear cardiology, society for cardiovascular angiography and interventions, society of cardiovascular computed tomography, and the society for cardiovascular magnetic resonance endorsed by the American college of chest physicians and the society of critical care medicine. *J Am Coll Cardiol* 2007;50(2):187-204.
- Hoar PF, Mookerjee A, Stone JG, Wicks AE, Malm JR. Acute hemodynamic alterations after mitral valve

- replacement with the glutaraldehyde-treated porcine heterograft prosthesis. *Ann Thorac Surg* 1980;29(5):434-9.
20. Song X, Zhang C, Chen X, Chen Y, Shi Q, Niu Y, et al. An excellent result of surgical treatment in patients with severe pulmonary arterial hypertension following mitral valve disease. *J Cardiothorac Surg* 2015;10(1):70.
21. Nellessen U, Inselmann G, Ludwig J, Jahns R, Capell AJ, Eigel P. Rest and exercise hemodynamics before and after valve replacement—a combined Doppler/catheter study. *Clin Cardiol* 2000;23(1):32-8.
22. Mubeen M, Singh AK, Agarwal SK, Pillai J, Kapoor S, Srivastava AK. Mitral valve replacement in severe pulmonary arterial hypertension. *Asian Cardiovasc Thorac Ann* 2008;16(1):37-42.
23. Alsaddique AA. Mitral valve replacement with the preservation of the entire valve apparatus. *Braz J Cardiovasc Surg* 2007;22(2):218-23.
24. Benmimoun EG, Friedli B, Rutishauser W, Faidutti B. Mitral valve replacement in children. Comparative study of pre-and postoperative haemodynamics and left ventricular function. *Br Heart J*. 1982;48(2):117-24.
25. Mangoni AA, Koelling TM, Meyer GS, Akins CW, Fifer MA. Outcome following mitral valve replacement in patients with mitral stenosis and moderately reduced left ventricular ejection fraction. *Eur J Cardiothorac Surg* 2002;22(1):90-4.
26. Lee SH, Chang BC, Youn Y-N, Joo HC, Yoo K-J, Lee S. Impact of prosthesis-patient mismatch after mitral valve replacement in rheumatic population: Does mitral position prosthesis-patient mismatch really exist? *J Cardiothorac Surg* 2017;12(1):88.