ISSN 2394–806X (Print), ISSN 2454-5139 (Electronic)
IJHRMLP, Vol: 06 No: 01, January, 2020
Printed in India

ORIGINAL RESEARCH PAPER

Histology of seeds: sprouting the neurons for diagnosis of poisoning

Saiyed MZG[1], Jani CB[2]

Received on May 14, 2019; editorial approval on August 17, 2019

ABSTRACT

Introduction: *The regulated and recommended consumption of different plants is for nutrition but, their irrational use either by accident, suicide or homicide can lead to illness, disease or even death in certain cases and is considered as poisoning. It is extremely difficult to detect the biological poisons at the laboratories in the samples collected from the patient. Its physical characteristics and histological features are useful in diagnosis. As per best of our knowledge, no database is available regarding the physical and histological characteristics of routinely consumed toxic seeds in biomedical literature. An attempt is made to prepare a pictorial database of physical and microscopic characteristics of frequently consumed seeds of toxicological significance in Gujarat region.* ***Materials and methods:*** *Toxic seeds commonly encountered in poisoning cases, procured from the local shop, were subjected to conventional method of tissue processing at Histopathology laboratory. The slides were examined under light microscope and photographs were captured. The photographs were processed in Microsoft office picture manager software and were reproduced with better resolution.* ***Results:*** *The images of the histological features of different seeds were produced and the characteristic features were identified.* ***Conclusion:*** *A pictorial database of histology of toxic seeds commonly causing poisoning in the Gujarat region is created. It is suggested to the Forensic Medicine departments in different medical colleges to carry out such exercise to create their regional database. Better images of histological features can be produced by using standard method of processing of toxic seeds in sophisticated Botanical laboratories & area of Forensic Botany can be explored further.*

Keywords*: Biological poison; forensic Botany; toxic seeds.*

INTRODUCTION

Nature has provided a lot of blessings for its creations in this world. Food is one of its blessings for the survival of the living. The plants have served as a good source of nutrition to not only the human beings but also the other creatures on this planet. Different parts of certain plants are very frequently consumed by human beings for nutrition purpose. The recommended and regulated consumption of such eatables is for nutrition, but irrational use of them by accident, suicide or homicide can lead to illness, disease or even death and is considered as poisoning. It is extremely difficult to detect the biological poisons at the laboratories in the samples collected from the patient. Its physical characteristics and histological features may play a key role in diagnosis of poisoning when these poisons are brought by the relatives of the patient or the remains of the poisons are found in the gastric lavage. As per best of our knowledge, no database is available regarding the physical and histological characteristics of routinely used/abused toxic seeds in biomedical literature. This kind of information which can serve as a single point ready reference is not available in a single compiled piece of literature or book,

Address for correspondence:
[1]Associate Professor (**Corresponding author**)
Mobile: +919662737129
Email: dr_ziya_saiyed@yahoo.com
[2]Professor and Head
Mobile: +919978986468
Email: fm.chetan@gmail.com
Department of Forensic Medicine and Toxicology
GCS Medical College, Hospital and Research Centre
Ahmedabad-380025, Gujarat, India.

Cite this article as: *Saiyed MZG, Jani CB. Histology of seeds: sprouting the neurons for diagnosis of poisoning. Int J Health Res Medico Leg Prae 2020 January;6(1):28-33. DOI 10.31741/ijhrmlp.v6.i1.2020.6*

even in botany. The authors have tried to prepare a pictorial database of histology of toxic seeds in the constrained set up of a medical college as compared to the sophisticated infrastructure for processing of the seeds available in the departments of botany elsewhere. But in spite of the limitations, the results obtained and recorded by the authors surprisingly approach the standard results in a standard set up. The study aims a) to create a pictorial database of histology of toxic seeds commonly causing poisoning, for their identification to aid in diagnosis b) to establish a histological confirmation of commonly encountered toxic seeds as a helpful adjunct to their identification based on their physical and clinical features and c) to check the utility of conventional method of tissue processing for histology of toxic seeds.

MATERIALS AND METHODS

Various toxic seeds were procured from the local shop. They were identified by gross features. Those included are seeds of 1) Poppy 2) Datura 3) Moringa oleifera 4) Argemone mexicana 5) Semecarpus anacardium 6) Abrus precatorious,7) Strychnos nux vomica 8) Croton tiglium 9) Capsicum annum and 10) Jatropha curcas.

The seeds were subjected to conventional method of tissue processing[1] at Histopathology laboratory in our hospital, were stained with Haematoxylin & Eosin (H&E) and slides were prepared. The slides were examined under light microscope in various magnifications (10X, 40X) and photographs were captured. The photographs were processed in Microsoft office picture manager software and were reproduced with better resolution.

RESULTS

Following are the images of the histological sections prepared out of the ten toxic seeds (**Figure 1** to **Figure 15**). Sections of Poppy seed in **Figure 1** and **2** show coating layer - testa, slightly curved embryo and cotyledons. Section of Datura seed in **Figure 3** shows outwardly curved embryo and thick walled lignified cells around it. **Figure 4** shows section of Moringa oleifera seed with testa represented by tangentially elongated cells followed by thin walled cells from outer to inner side. Cotyledon is made up of parenchymatous cells with oil globules within. Section of Argemone Mexicana seed in **Figure 5** shows outer coating layer with flat cells and embryo in the centre. **Figure 6** depicts section of Semecarpus anacardium seed showing outermost elongated, lignified cells of pericarp followed by mesocarpal parenchymatous cells with lysigenous cavities. Inner to these layers are layer of thin testa and parenchymatous cotyledon. **Figure 7** and **8** are representing sections of Abrus precatorius seed with outermost layer of testa – radially much elongated cells, arranged irregularly followed by tagmen inner to it and innermost parenchymatous cotyledon with vascular network within it. Section of seed of Strychnos Nux vomica in **Figure 9** is showing collapsed parenchymatous cells of testa with brownish contents and thick walled, cellulosic polyhedral cells of endosperm inner to it. **Figure 10** and **11** are representing the sections of Ricinus communis seed showing cells of testa elongated radially and mesophyl cells with oil globules in the cotyledon. Dicotyledonous curved embryo is visible in section of Capsicum annum seed in **Figure 12** and **13**. **Figure 14** and **15** are depicting sections of Jatropha curcas seed which shows polygonal cells with slit like lumen.

Images of gross appearance of these seeds are not provided due to space constraint. The same can be availed through e-mail to the corresponding author.

FIGURES:

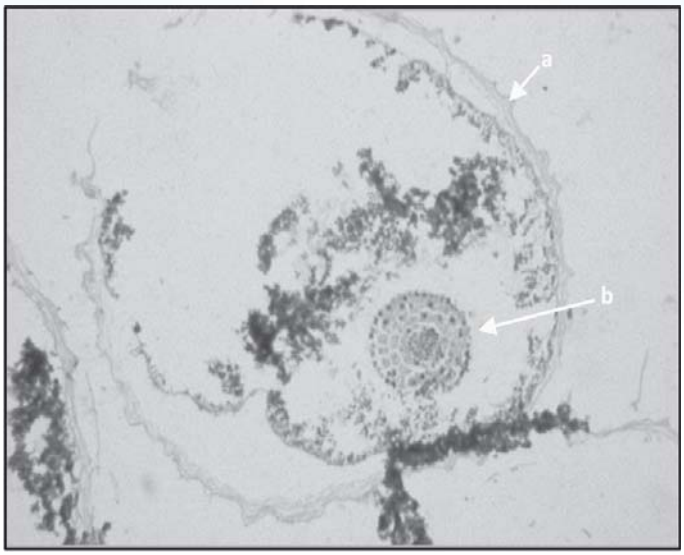

Figure 1 Transverse section of Poppy seed (10X) showing **a.** Testa, **b.** Embryo

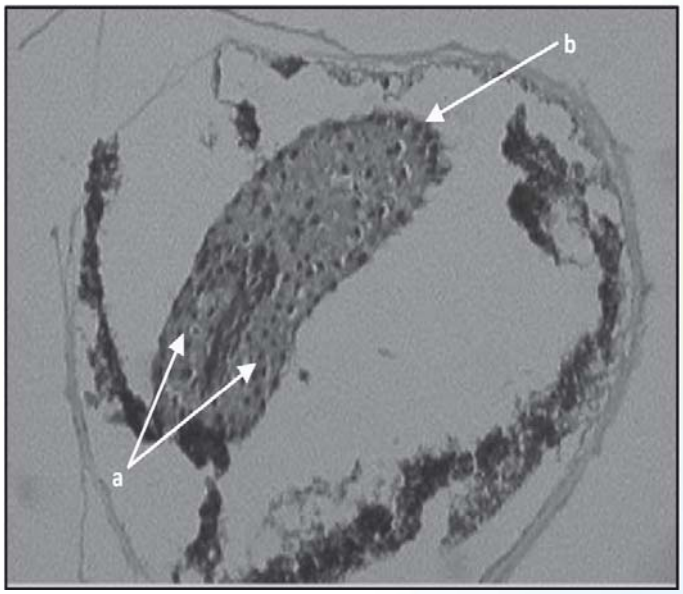

Figure 2 Longitudinal Section of Poppy seed (10X) showing **a.** Cotyledons, **b.** Shoot apex

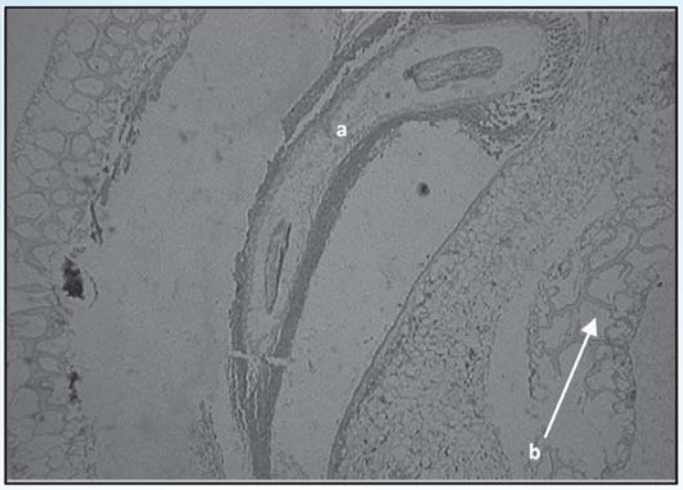

Figure 3 Longitudinal section of Datura seed (10X) showing **a.** Curved embryo, **b.** Lignified cells

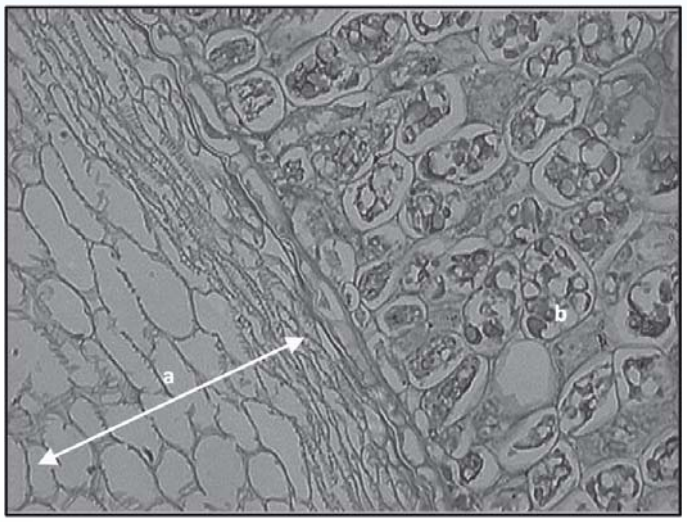

Figure 4 Transverse section of Moringa oleifera seed (40X) showing **a.** Tangentially elongated cells followed by thin walled cells of Testa, **b.** Parenchymatous cotyledon cells

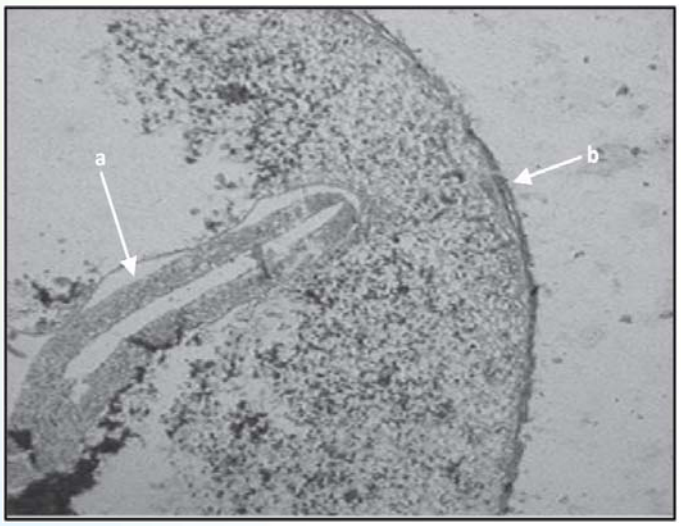

Figure 5 Longitudinal section of Argemone Mexicana seed (10X) showing **a.** Embryo, **b.** Collapsed cells of Testa

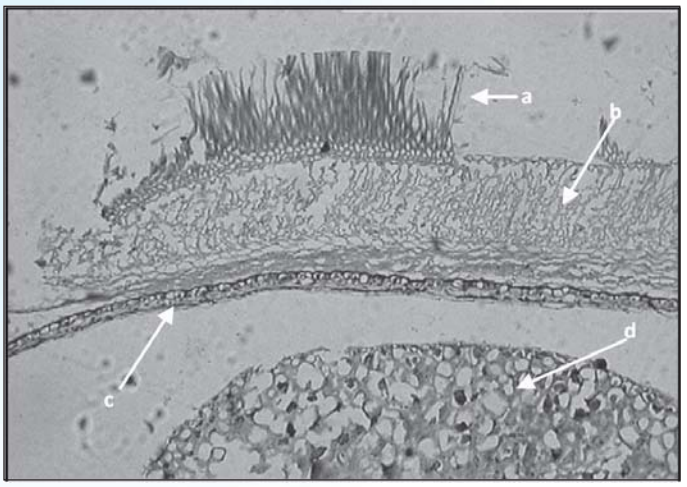

Figure 6 Longitudinal section of Semecarpus Anacardium seed (40X) showing **a.** Lignified elongated cells of pericarp, **b.** Mesocarpal parenchymatous cells with lysigenous cavities, **c.** Testa, **d.** Parenchymatous cotyledon

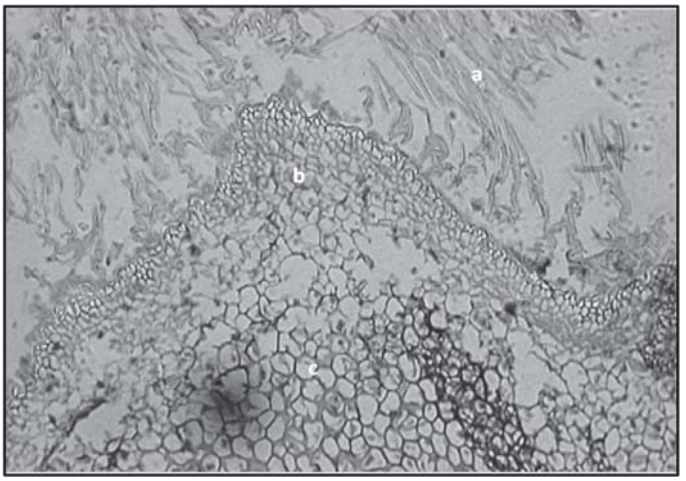

Figure 7 Transverse section of Abrus Precatorius seed (10X) howing **a.** Testa, **b.** Tegmen, **c.** Parenchymatous cotyledon

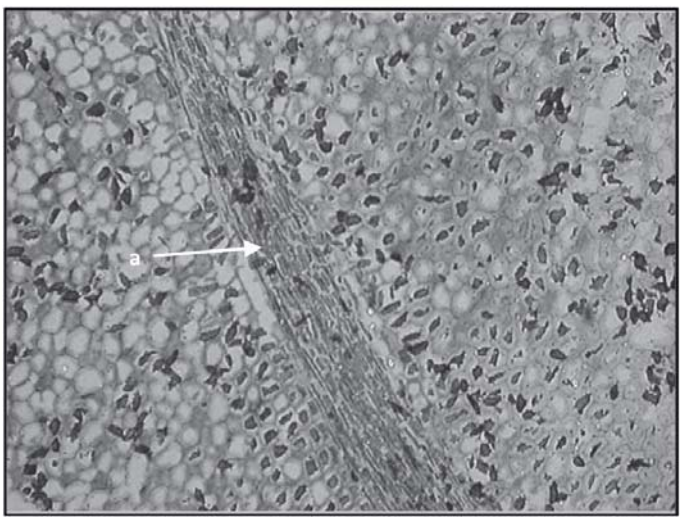

Figure 8 Transverse section of Abrus Precatorius seed (40X) showing **a.** Vascular network within cotyledon

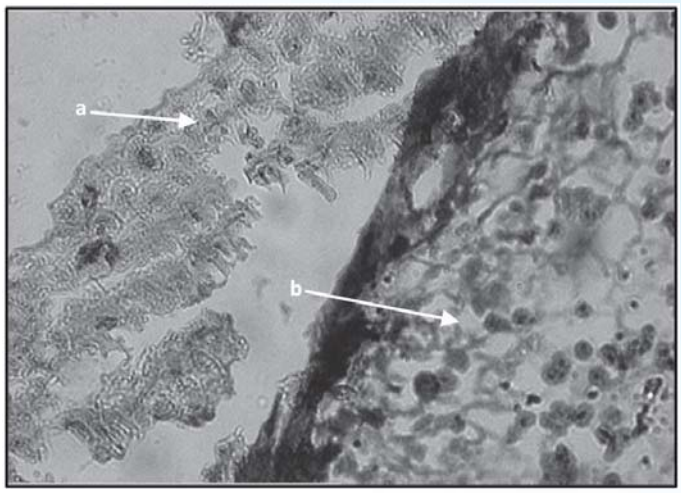

Figure 9 Transverse section of Strychnos Nux Vomica seed (40X) showing **a.** Collapsed parenchymatous cells of testa with brownish contents, **b.** Thick walled, cellulosic polyhedral cells of endosperm

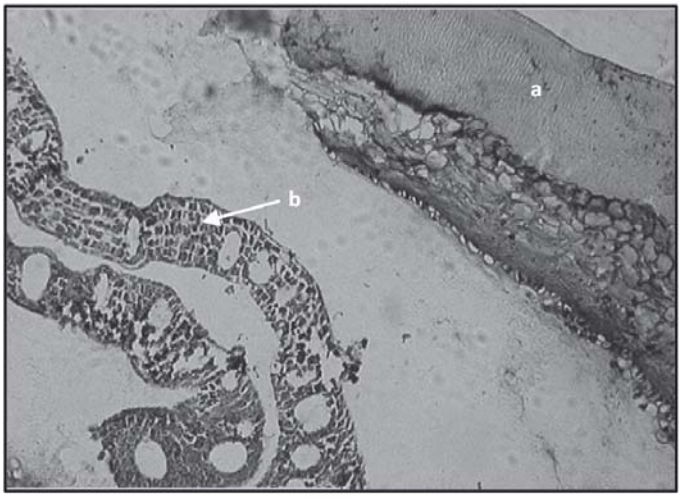

Figure 10 Transverse section of Croton Tiglium seed (40X) showing **a.** Radially elongated epidermal cells of testa, **b.** Cotyledon

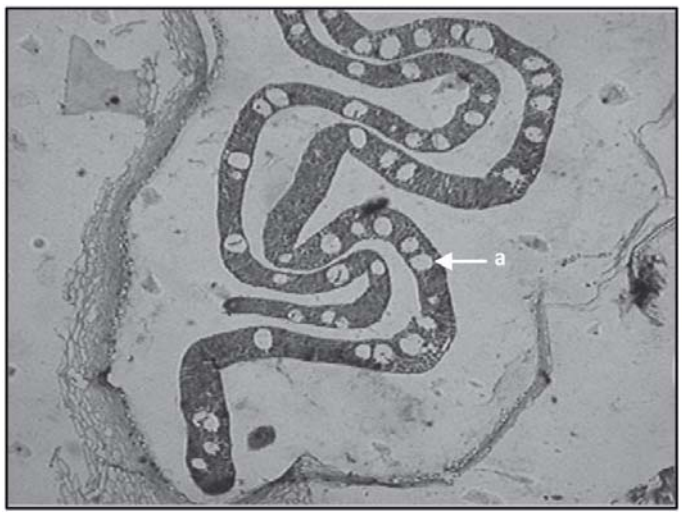

Figure 11 Transverse section of Croton Tiglium seed (10X) showing **a.** Cotyledon – Mesophyl cells with oil globules

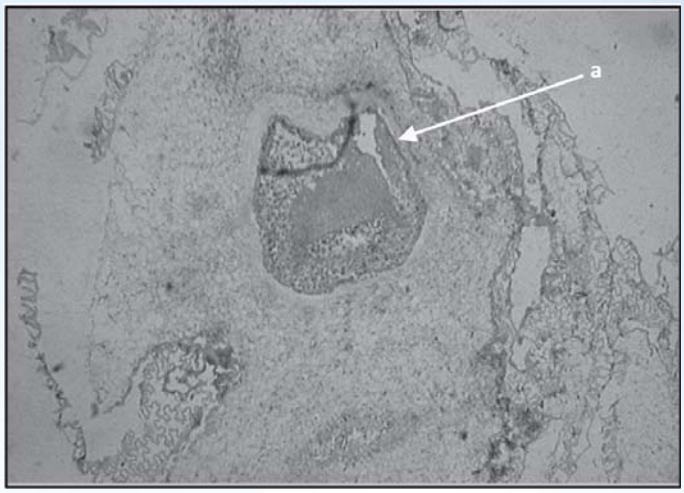

Figure 12 Transverse section of Capsicum annum seed (10X) showing **a.** Embryo

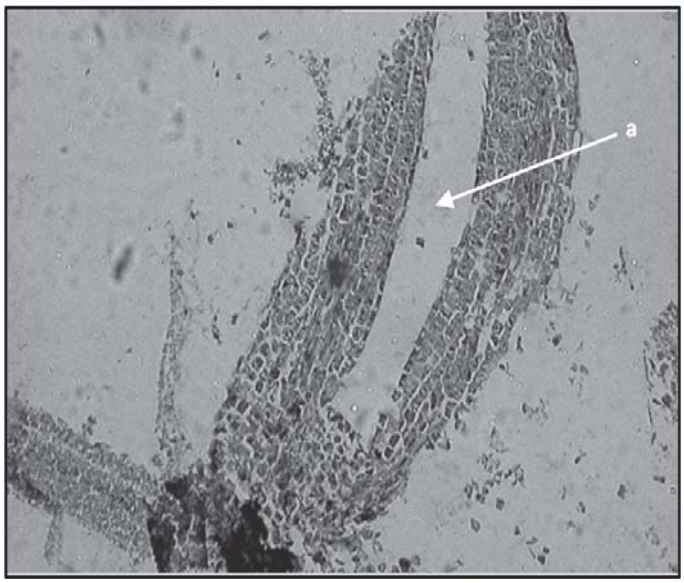

Figure 13 Longitudinal section of Capsicum annum seed (10X) showing **a.** Dicotyledonous curved embryo

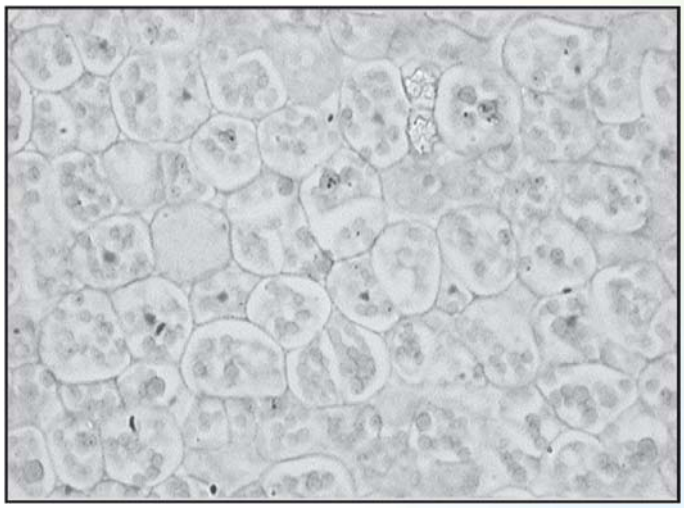

Figure 14 Transverse section of Jatropha Curcas seed (40X) showing Polygonal cells with slit like lumen

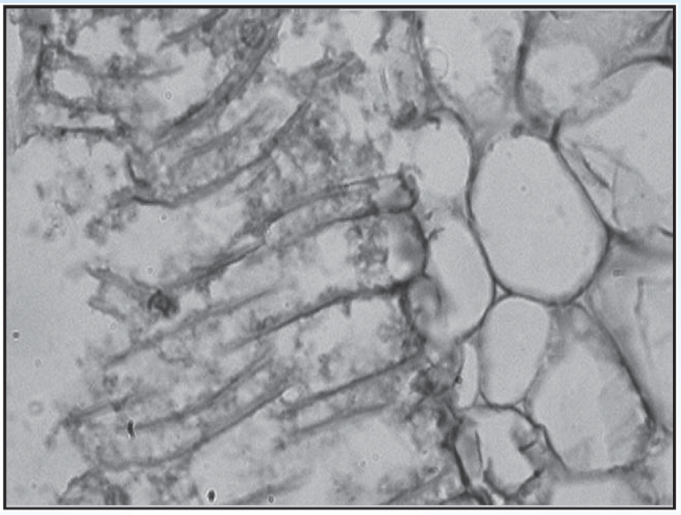

Figure 15 Longitudinal section of Jatropha curcas seed (100X – Oil immersion) showing Polygonal cells with thickened walls

DISCUSSION

The authors encountered a case where a pediatric patient consumed unknown seeds and presented with severe vomiting and diarrhoea, where the pediatrician was confused with the diagnosis, but the diagnosis of poisoning with Jatropha curcas seeds was confirmed by the exercise of gross as well as histological examination of the seeds brought by relatives of the patient.[2] This exercise was collaboratively carried out by Pediatrics & Forensic Medicine departments. The authors were encouraged to create a histological database for other toxic seeds commonly causing poisoning in the region by success of the case mentioned in reference 2.

The images of gross physical characteristics of various toxic seeds were found in plenty of literature[3-9] and the features were compared. The authors found compatible literature of histology of some seeds from The Ayurvedic Pharmacopoeia of India[10-14] with which the slides were compared and confirmed, but no references for the images of histological features of these toxic seeds were found. The seeds were subjected to the conventional method of tissue processing at Histopathology laboratory of the hospital which yielded confirmatory results in some, but not all. This might be because the sectioning could not be done properly; which is attributable to the hardness of the seeds, as opposed to the human tissues which have softer consistency. However, the seeds if soaked in alcohol before sectioning can yield better sections. Stains like Safranin & Methylene blue can be better substitutes to H & E stain; & parallel staining with Sudan can help easier identification of lipid filled cells. The standard procedure for sectioning of seeds mentioned by Willard W. Rowlee[15] can yield better results when carried out in a sophisticated Forensic Botany laboratory with compatible instruments and stains for the seeds.

CONCLUSIONS

A pictorial database of histology of toxic seeds commonly causing poisoning in the Gujarat region is created. The seeds brought by the patient or relatives, recovered from the crime scene or by filtering the gastric lavage contents can be collected and their histology can be compared with the database as an adjunct to their physical features for its identification in cases of poisoning with biological poisons where, these poisons are not being able to be detected routinely in Forensic science laboratories. Forensic Medicine departments in different medical colleges are suggested to carry out such an exercise to create their own regional database. Better images of histological features can be produced by using standard method of processing of toxic seeds in sophisticated Botanical laboratories and this area of Forensic Botany can be explored further.

Ethical clearance: Not required as this study does not involve human participants.

Acknowledgements: The authors are thankful to the Department of Pathology, GCSMCH & RC, Ahmedabad for their support in processing of the seeds. The authors are also grateful to Dr Afroz Bloch, Assistant Professor, Microbiology, GCSMCH & RC, Ahmedabad and Mr. Yasin Bloch, Retired Botanist for their valuable support.

Conflict of interest: None declared.

Author's contribution: We declare that this work was done by the authors named in this article and all liabilities pertaining to claims relating to content of this article shall be borne by the authors. Concept, Design, Manuscript writing by: Dr Mohammed Ziyauddin G Saiyed, Dr Chetan B Jani. Processing of the seeds & identification of the features on sections were done by the authors with the help of personnel mentioned in acknowledgements.

REFERENCES

1. Ramnik Sood. Histopathology. In: Medical laboratory technology - methods and interpretations. 4th ed. New Delhi: Jaypee Brothers; 1994. p. 586-93.
2. Saiyed MZ, Prajapati S, Jani CB, Prajapati BS. Paediatric poisoning panic and Forensic Toxicologist. JIAFM 2015;37(4): 435-7.
3. Mathiharan K, Patnaik AK, editors. Modi's medical jurisprudence and toxicology. 23rd ed. Nagpur: Butterworths Wadhwa; 2005. Sec. II. p. 219-26,231-2,251-5,289-90,401-7,433-43.
4. Reddy KSN, Murty OP. The essentials of Forensic medicine and toxicology. 34th ed. New Delhi: Jaypee Brothers Medical Publishers (P) Ltd; 2017. p. 516-7,543,556-7,569,593.
5. Pillay VV. Textbook of Forensic Medicine & Toxicology. 19th ed. Hyderabad: Paras Medical Publishers; 2019. p. 576-82,588,613-4,656-8,664-5,720-1.

6. Vij K. Textbook of Forensic medicine & toxicology – principles and practice. 6th ed. New Delhi: Reed Elsevier India Private Limited; 2014. p. 446-8,456,482,520-1.

7. Nandy A. Principles of Forensic medicine including toxicology. 2nd ed. Kolkata: New Central Book Agency (P) Ltd; 2007. p. 498,500,502,518,545-5,544.

8. Goswami DK, Das B. An atlas of poisonous plants. 1st ed. Guwahati: Seven Star Publications Pvt. Ltd. and Department of Agada Tantra and Vidhi Ayurveda, Govt. Ayurvedic College, Guwahati Assam; 2012. p. 27-48,55-9,61-5.

9. Aggrawal A. Forensic medicine and toxicology for MBBS. 1st ed. Sirmour: Avichal Publishing Company; 2016. p. 532-7,555-6,579,596,608.

10. Department of Indian Systems of Medicine & Homeopathy. The Ayurvedic Pharmacopoeia of India. New Delhi: Ministry of Health & Family Welfare, Government of India; 1999. Part I (Vol. I). p. 58.

11. Department of Indian Systems of Medicine & Homeopathy. The Ayurvedic Pharmacopoeia of India. New Delhi: Ministry of Health & Family Welfare, Government of India; 1999. Part I (Vol. II). p. 19-20,61-2.

12. Department of Indian Systems of Medicine & Homeopathy. The Ayurvedic Pharmacopoeia of India. New Delhi: Ministry of Health & Family Welfare, Government of India; 1999. Part I (Vol. III). p. 43.

13. Department of Indian Systems of Medicine & Homeopathy. The Ayurvedic Pharmacopoeia of India. New Delhi: Ministry of Health & Family Welfare, Government of India; 1999. Part I (Vol. IV). p. 29-31,127.

14. Department of Indian Systems of Medicine & Homeopathy. The Ayurvedic Pharmacopoeia of India. New Delhi: Ministry of Health & Family Welfare, Government of India; 1999. Part I (Vol. V). p. 33-4,91-2.

15. Americal Society of Microscopists. Proceedings of the American Society of Microscopists in Thirteenth Annual Meeting; 1890. Vol. 12. p. 113-5.